

Jod-Basedow Syndrome Following Oral Iodine and Radioiodinated-Antibody Administration

Ayda M. El-Shirbiny, Stavross S. Stavrou, Ann Dnistrian, Martin Sonenberg, Steven M. Larson and Chaitanya R. Divgi
Nuclear Medicine Section, Department of Radiology, Memorial Sloan-Kettering Cancer Center, New York, New York

This is a case of thyrotoxicosis, presumably due to Jod-Basedow syndrome, after stable iodine ingestion for thyroid blockade in a patient with ovarian carcinoma having ^{131}I -labeled monoclonal antibody imaging. With the increased use of radioiodinated antibodies, for therapy and imaging, this possible side effect of excess stable iodine administration should be noted, especially in patients with pre-existing goiter.

Key Words: hyperthyroidism; iodide ingestion; radioiodinated antibody

J Nucl Med 1997; 38:1816-1817

Iodine is essential for thyroid hormone synthesis. Iodine uptake may be several times the normal requirement, depending on dietary or drug intake. Iodine deficiency, such as occurs in mountainous areas as the Andes, can lead to goiter. Endemic goiter represents an adaptation to iodine deficiency that is brought about by an increase in TSH.

Iodine excess can lead to untoward thyroid complications, such as iodide goiter, iodide-induced hypothyroidism (1,2) and iodide-induced subacute thyroiditis (3). Iodine-induced thyrotoxicosis (Jod-Basedow) is also a complication of iodine excess (1,4-8).

Excessive quantities of iodine are encountered in medicinal preparations or in radiographic contrast media. Radiographic contrast media contain the largest quantities, however, commonly used drugs such as SSKI, Lugol's iodine and Amiodarone also contain large quantities of iodine (9,10).

The mechanism of autoregulation, when exposed to iodine excess, is such that increased iodine leads to increased transport. The resulting expansion of the iodine pool leads to decreased hormone synthesis and autoregulatory inhibition of iodine transport, a phenomenon known as the Wolff Chaikoff effect (11).

Defective or absent autoregulatory mechanisms lead to pathologic consequences of iodine excess (9). Failure of escape from the Wolff Chaikoff effect leads to sustained inhibition of hormonal synthesis resulting in an increase in TSH and enlargement of the thyroid gland, which often leads to goiter and hypothyroidism. These two conditions are self-limiting and subside when iodine levels return to normal.

Jod-Basedow disease occurs when there is excess iodine and absent autoregulation. In this condition, excess iodine leads to a sustained increase in hormone synthesis and, eventually, thyrotoxicosis. It is characterized by decreased radioactive iodine uptake due to an expanded iodine pool and inhibition of TSH stimulation. Rarely, iodine excess may cause acute onset thyroiditis with painful swelling of the thyroid gland that subsides after withdrawal of iodine (12).

We report the case of a patient with ovarian carcinoma who

developed hyperthyroidism after receiving SSKI as part of a protocol for ^{131}I monoclonal antibody treatment.

CASE REPORT

The patient was a 74-yr-old white woman with metastatic ovarian CA, treated earlier with debulking and systemic paclitaxel and Cis-platinum. She had NIDDM and stable hypertension controlled with diltiazem. The patient entered a radioimmunodetection protocol, approved by the Institution Review Board (IRB# 94-13), using ^{131}I MX35 F(ab')₂ to ovarian tissue, administered IV 4 days before laparotomy. Per protocol, she received SSKI (1 mg/ml), 10 drops orally three times daily, starting October 6, 1995 and continuing until surgery on October 10, 1995, for a total dose of 18 mg of iodine. Baseline thyroid function tests were normal, however, thyroglobulin was elevated (Table 1). Approximately 4 hr following the antibody injection, she developed dyspnea and tightness of the chest that responded promptly to oral Benadryl. There was no fever or pruritus. The next night she felt a tender node below the chin on the right side with no evidence of throat soreness. On examination 2 days later, a small, minimally tender submental lymph node was palpable. There was no appreciable thyromegaly. The patient had an exploratory laparotomy with debulking of the residual tumor on October 10, 1995 with an uneventful course. Chemotherapy with IV paclitaxel and IP Cis-platinum was started on November 3, 1995. A total of 2 liters normal saline was injected intraperitoneally. On November 6, she developed dyspnea and sharp chest pain. She was transferred to the ICU, where she was treated for pulmonary edema and new onset atrial fibrillation. Thyroid function tests, as part of the evaluation of atrial fibrillation on November 6, showed elevated T3 and T4 and low TSH. (Table 1). Subsequently, the patient was referred to the endocrinology clinic. Her heart rate was 92 bpm. Measurement by exophthalmometer revealed bilateral exophthalmos 190 + 95 mm. On careful examination, the thyroid was now enlarged, nontender, with the left lobe more prominent than the right. Mild tremors in hands and brisk reflexes were noted in upper and lower extremities.

The patient was referred to the nuclear medicine service for thyroid imaging and a 24-hr uptake. The thyroid image was taken on October 22 after 10 mCi TcO₄ IV (Fig. 1), approximately 6 wk after starting SSKI, showed an enlarged thyroid gland with faint asymmetrical uptake and the right lobe larger than the left. Thyroid uptake was 10% at 24 hr postinjection of 30 μCi of ^{131}I . The patient was clinically controlled on beta-blockers. Subsequent thyroid function tests showed a gradual decrease of T3 and T4 levels (Table 1). On December 14, 1995, both antithyroglobulin antibody and antimicrosomal antibody were negative. A repeat thyroid image obtained on January 11, 1996, approximately 7 wk later, (Fig. 2), showed increased uptake compared to the previous image with further reduction in thyroid size and more homogenous tracer distribution. The 24-hr iodine uptake at that time was 20.8%. Serum iodine at that time was 8 $\mu\text{g}/\text{ml}$ (normal = 0-5).

The last serum sample of January 11, 1996 was assayed with and without the addition of antibody because of the possibility of the presence of human antimouse antibody (HAMA) interfering with

Received Jul. 8, 1996; revision accepted Jan. 27, 1997.

For correspondence or reprints contact: C.R. Divgi, MD, Nuclear Medicine Service, Memorial Sloan-Kettering Cancer Center, 1275 York Ave., New York, NY 10021.

TABLE 1
Serial Thyroid Function Tests

Test (Ref. range)	TSH (0.46–3.6) μU/ml	T3 (86–187) ng/dl	T4 (4–12) μg/dl	T3 uptake (85–115%)	Thyroglobulin (2.7–21.0) ng/ml
10/06/95	2.4	116	9.7	ND	90.5
11/08/95	0.2	332	17.1	106	ND
12/01/95	0.1	150	12.7	93	147.7
12/14/95	0.1	86	11.8	77	150
01/11/96	0.1	59	11.2	106	52.6

any of these laboratory tests, especially thyroglobulin. There was no effect on the results of both samples.

DISCUSSION

The patient presented with an episode of hyperthyroidism, which was self-limited and resolved without any treatment after discontinuing SSKI. The elevated T3 and T4 and low TSH with low 24-hr ¹³¹I uptake and the self-limiting nature of the disease exclude Graves' disease. The elevated baseline thyroglobulin suggests preexisting goiter. This probably predisposed the patient to developing thyrotoxicosis after stable iodide ingestion.

Subacute thyroiditis results in slightly painful enlargement of the thyroid gland. Initially, there is leakage of colloid from the thyroid leading to elevation of T3 and T4 and, accordingly, depressed TSH (13). In addition, thyroglobulin will increase and may remain elevated long after subsidence of the inflammatory process (14). Characteristically, the 24-hr radioactive iodine uptake is low. Thyroid imaging may show very low, patchy, uptake or no uptake at all (15,16). Tests of thyroid antibody are positive in only a small percentage of cases (17).

On the other hand, iodine-induced thyrotoxicosis, or Jod-Basedow disease, occurs in endemic or nonendemic regions (18). Most of the patients have multinodular goiter. The elevated thyroglobulin before treatment (Table 1) in our patient may indicate this, or thyroid adenoma, with autonomously functioning tissue that transports iodine poorly. Thyrotoxicosis

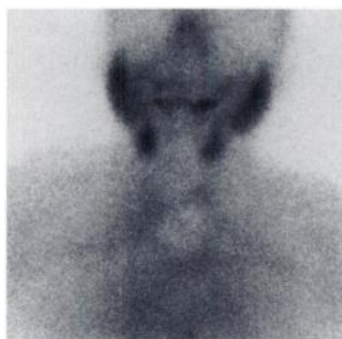

FIGURE 1. Initial TcO4 image shows mild uptake and thyroid enlargement, with the right lobe more than the left.

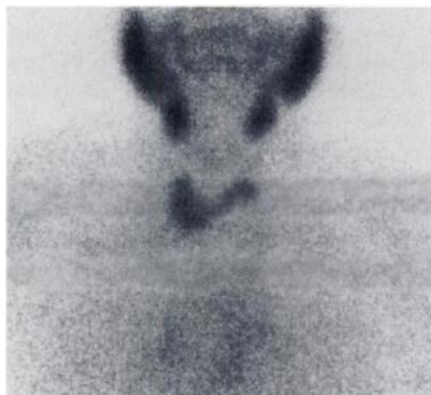

FIGURE 2. Follow-up TcO4 thyroid image shows increased uptake, further reduction in thyroid size and more homogeneous uptake.

will occur several weeks or months after receiving pharmacologic doses of iodine containing radiographic contrast agents or iodine containing drugs or inorganic iodide. Serum iodine concentration must increase sufficiently so that enough iodide can enter the thyroid to allow excessive thyroid hormone synthesis and secretion by autonomous thyroid tissue. Serum thyroglobulin is also increased, in most cases, with thyrotoxicosis (19).

An interesting feature of the images was that the decrease in tracer concentration was not uniform throughout the gland, being relatively less in the left lobe. This is consistent with the observations that iodide-trapping changes after excess iodide ingestion may not affect the gland uniformly (20).

A recent literature search did not reveal instances of thyroid function disturbance after administration of ¹³¹I-labeled compounds, such as MIBG and antibodies. With the increasing use of radioiodinated antibodies and other pharmaceuticals for therapy, it is important to be aware of the side-effects of excess stable iodide administration. Reported changes in thyroid function after radioimmunotherapy have been limited to increases in serum TSH values (21). These were believed to be due to induction of subclinical hypothyroidism subsequent to trapping of free radioiodide by the thyroid, with subsequent radiation damage. Spurious elevations in serum TSH may also, depending on the assay method used, represent cross-reactivity with human antimouse antibody (22). The clinical investigator and clinician need to be aware of the possibility, albeit remote, of thyroid dysfunction due to stable iodide administration.

REFERENCES

- Fradkin JH, Wolff J. Iodine-induced thyrotoxicosis. *Medicine* 1983;62:1-20.
- Wolff J. Iodine goiter and the pharmacologic effects of excess iodide. *Am J Med* 1969;47:101-124.
- Edmunds HT. Acute thyroiditis from potassium iodide. *Br Med J* 1955;230:354-356.
- Kohn LA. The midwestern American 'epidemic' of iodine-induced hyperthyroidism in the 1920s. *Bull NY Acad Med* 1976;52:720-781.
- Vagenakis AG, Wang C, Burger A, Maloof F, Braverman LE, Ingbar SH. Iodine-induced thyrotoxicosis in Boston. *New Engl J Med* 1972;287:523-527.
- Skare S, Frey HMM. Iodine-induced thyrotoxicosis in apparently normal thyroid glands. *Acta Endocr, Copenh* 1980;94:332-336.
- Kallee E, Wahl R, Bohnert J, Dohm D, Fessler E. Thyrotoxicosis by iodine-containing drugs. *J Mol Med* 1980;4:221-224.
- Léger AF, Massin JP, Laurent MF, Vincens M, Auriol M, Helal OB, Chomette G, Savoie JC. Iodine-induced thyrotoxicosis: analysis of eighty-five consecutive cases. *Eur J Clin Invest* 1984;14:449-455.
- Woerber KA. Iodine and thyroid disease. *Medical Clinics of North America*. 1991;75:169-178.
- Martino E, Aghin-Lombardi F, Mariotti S, Bartalina L, Braverman L, Pinchera A. Amiodarone: a common source of iodine-induced thyrotoxicosis. *Horm Res* 1987;26:158-171.
- Wolff J, Chaikoff JL. Plasma inorganic iodide as homeostatic regulators of thyroid function. *J Biol Chem* 1948;174:555.
- Edmunds HT. Acute thyroiditis from potassium iodide. *Br Med J* 1955;1:354.
- Ingbar SH, Freinkel N. Thyroid function and metabolism of iodine in patients with subacute thyroiditis. *Arch Intern Med* 1958;101:339-346.
- Izumi M, Larsen PR. Correlation of sequential change in serum thyroglobulin, triiodothyronine and thyroxine in patients with Graves disease and subacute thyroiditis. *Metabolism* 1978;27:449-460.
- Lewitus W, Rechin J, Lubin E. Sequential scanning of the thyroid as an aid to the diagnosis of subacute thyroiditis. *Israel J Med Sci* 1967;3:847-854.
- Hamburger JI, Kadian J, Rossin HW. Subacute thyroiditis-evaluations depicted by serial ¹³¹I scintigrams. *J Nucl Med* 1965;6:560-565.
- Bech K, Feld-Rasmussen U, Bliddal H, et al. Persistence of autoimmune reactions during recovery of subacute thyroiditis. In: Pinchera A, Ingbar SH, McKenzie JM, Fenzi GF, eds. *Thyroid autoimmunity*. New York, NY: Plenum Press; 1987:623-625.
- Fradkin JE, Wolff J. Iodine-induced thyrotoxicosis. *Medicine (Baltimore)* 1984;62:1.
- Van Hurler AJ, Vassart G, Dumont JE. Control of thyroglobulin synthesis and secretion. *N Engl J Med* 1979;301:239.
- Hugo S, Jacob P, Gerber H. Natural heterogeneity of thyroid cells; the basis for understanding thyroid function and nodular goiter growth. *Endocr Rev* 1989;10:125-135.
- Press OW, Eary JF, Appelbaum FR, Martin PJ, Badger CC, Nelp WB, et al. Radiolabeled-antibody therapy of B-cell lymphoma with autologous bone marrow support. *N Engl J Med*: 1993;329:1219-24.
- Schwartz MA, Lovett DR, Redner A, Finn RD, Graham MC, Divgi CR, et al. Dose-escalation trial of M195 labeled with iodine-131 for cytoreduction and marrow ablation in relapsed or refractory myeloid leukemias. *J Clin Oncol* 1993;11:294-303.



The Journal of
NUCLEAR MEDICINE

Jod-Basedow Syndrome Following Oral Iodine and Radioiodinated-Antibody Administration

Ayda M. El-Shirbiny, Stavross S. Stavrou, Ann Dnistrian, Martin Sonenberg, Steven M. Larson and Chaitanya R. Divgi

J Nucl Med. 1997;38:1816-1817.


This article and updated information are available at:
<http://jnm.snmjournals.org/content/38/11/1816>

Information about reproducing figures, tables, or other portions of this article can be found online at:
<http://jnm.snmjournals.org/site/misc/permission.xhtml>

Information about subscriptions to JNM can be found at:
<http://jnm.snmjournals.org/site/subscriptions/online.xhtml>

The Journal of Nuclear Medicine is published monthly.
SNMMI | Society of Nuclear Medicine and Molecular Imaging
1850 Samuel Morse Drive, Reston, VA 20190.
(Print ISSN: 0161-5505, Online ISSN: 2159-662X)

© Copyright 1997 SNMMI; all rights reserved.

 SOCIETY OF
NUCLEAR MEDICINE
AND MOLECULAR IMAGING