

Low Dose Naltrexone (LDN) for Cancer Treatment

LDN Research Trust Conference

www.ldnresearchtrust.org

Orlando, Feb 2016

Akbar Khan, M.D.

Research Trust

Disclosure

The presenter is the Medical Director of Medicor Cancer Centres Inc. where LDN is prescribed and dispensed for a fee, but without profit (by law). This clinic is owned by a family member of the presenter.

Research Trust

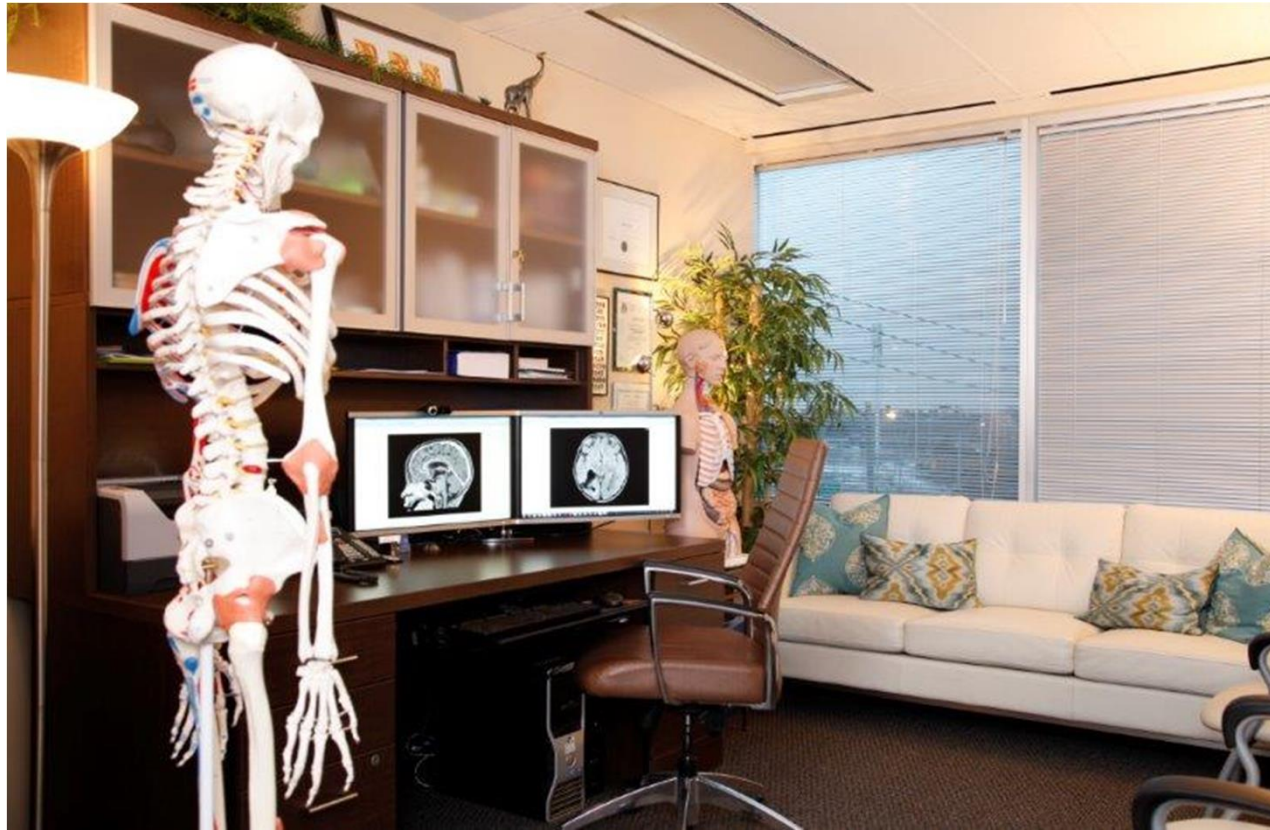Medicor Office



www.medicorcancer.com

Founded in 2006

Medicor Office



www.medicorcancer.com

Founded in 2006


Medicor Office




www.medicorcancer.com

Founded in 2006

Background

- Off-label use of LDN as a cancer therapy was discovered by Dr. Bernard Bihari
 - Mechanism as discussed
 - Brief opiate receptor blockade creates a surge in endorphin levels including OGF, a cell growth regulator
 - Block TLR4 signalling: modulates immune response
- 

Published Data - OGF

- Zagon et al. have studied OGF extensively
 - Found to kill colon¹, pancreas², squamous cell³, neuroblastoma⁴, renal cell⁵, triple neg. breast⁶, ovarian cancers⁷ (*in vitro*)
 - Phase 1 human trial of i.v. OGF in 16 pancreatic cancer patients showed improved survival over standard 5-FU or gemcitabine chemo, with good pain control⁸
- 


Published Data - LDN

- Very limited published cancer research
- Generic drug, too cheap? No R.O.I.
- Phase 2 breast cancer study – **terminated**¹
- Phase 2 study of melanoma, prostate, renal cell, **terminated**¹


1. www.clinicaltrials.gov



Published Data - LDN

- Phase 2 study of gliomas, when combining LDN with chemo / radiation , conducted in USA
Results: not published? data not analyzed?
Data is available on clinicaltrials.gov
improved QOL with LDN¹
 - Phase 2 randomized trial with 89 leukemia patients conducted in Iran
Results: **improved QOL** with LDN² ($p < 0.05$)
- 

Published Data - LDN

- Berkson et al. published convincing case reports of successful long-term treatment of **pancreatic cancer** using LDN + alpha lipoic acid¹
 - Responses confirmed by PET scans
 - Berkson also published a case of **B-cell lymphoma** response to LDN²
- 

Common Side Effects

OGF

- No significant side effects
- Hypotension or dizziness after infusion is possible

LDN

- Insomnia and vivid dreams are common - good or bad!



Good Side Effects / Benefits

- Improved mood
- Enhanced sense of well-being



Drug Interactions


- OGF – none known
- LDN – opiate antagonist, **do not use together** with opiates

Never use LDN in patients on continuous opiate medication! (time release oral, pain pump, pain patch, methadone). **Acute opiate withdrawal!**


Ok to use with intermittent short-acting daytime opiates, no opiate at bedtime. **Opiate won't work.**




Sample Protocol (adult)

- Escalating dose is preferable:
 - Start 2mg at bedtime, increase to 4 or 4.5mg gradually over 1-3 weeks according to side effects (insomnia/dreams)
 - Do not go over 5mg
 - Must be given at bedtime for max. effect
 - We use 1mg caps and 1mg/ml oral liquid, to allow dose escalation
- 


Sample Protocol (adult)

- May need treatment for insomnia
 - Consider natural medications with proven anti-cancer effects for synergism and improved sleep
 - HonoPure [™] (high potency magnolia extract)
 - Melatonin (up to 20mg at bedtime)
 - Can use benzodiazepine like lorazepam (avoid if possible)
- 


Sample Protocol (pediatric)

- Correct dose in children is not known
 - Estimated target: **0.1mg/kg/day at bedtime**
 - Start at ½ of this and increase gradually as in adults
 - Use naltrexone flavoured oral liquid 1mg/ml, and a 1ml syringe for measuring
 - Must be flavoured correctly (bitter otherwise)
 - Ask a skilled compounding pharmacist
- 


Our Experience

- > 350 cancer patients treated with LDN
 - Experience with LDN over a period of 9 years
 - Most patients received concurrent non-toxic therapy (e.g. natural medicines) so collection of specific response data on 350 patients is difficult
 - Carefully selected case reports are more useful
- 


Case 1 - lymphoma

- 55 year old female with lymphoma diagnosed by ultrasound
 - Refused standard therapy
 - LDN 4mg at bedtime + i.v. glutathione
 - Added HonoPure later for sleep
 - “extensive intraperitoneal and retroperitoneal lymphadenopathy” by ultrasound pre-treatment
- 


Case 1 - lymphoma

- ultrasound confirmed reduction of all nodes
 - Largest 3.4cm, gradually reduced to 1.7cm over 1 year
 - Patient continues to take LDN intermittently along with homeopathic and natural medicines more regularly
 - Remains alive and well 4 years later
- 


Case 2 – small bowel cancer

- 56 year old female with small bowel cancer
 - Prior surgery
 - Lung and liver metastases, responded to chemotherapy (partial response)
 - Chemo stopped, started LDN with natural medicines per naturopathic doctor
 - CT scan after 6 mo. of LDN: shrinkage of metastases
- 


Case 2 – small bowel cancer

- CT scan after 9 mo. of LDN: stable disease
 - CT scan after 12 mo. of LDN: mild re-growth noted
 - No side effects of therapy
 - Patient remains alive and asymptomatic
 - New treatment just started: **SEF** (“side effect-free”) **chemotherapy**, developed by Dr. Ken Matsumura of Berkeley, CA
- 


Case 3 – TCC bladder

- 65 year old male with aggressive bladder cancer (high grade transitional cell carcinoma)
 - Standard therapy: excision / cautery “TURBT”
 - Recurrent tumours, invasion into muscularis layer of bladder confirmed on biopsy
 - Advised to have radical surgery: cystectomy + ileal conduit (remove bladder, urine drains into a bag)
- 


Case 3 – TCC bladder

- Patient refused radical surgery, started LDN
 - Insomnia: prescribed zopiclone
 - Urologist then offered BCG
 - Patient took 1 course of BCG along with continuous LDN therapy
 - Repeat cystoscopy after 4 mo: no evidence of any cancer
 - Continued LDN x 1 yr only, cancer-free 7 yrs. later
- 


Case 4 – TCC bladder

- 70 year old male with bladder cancer (transitional cell carcinoma)
 - Standard therapy: excision / cautery “TURBT”
 - Recurrent tumours
 - Tried metabolic therapy, cancer grew back
 - Changed over to LDN, added HonoPure for sleep and for anti-cancer effects
- 


Case 4 – TCC bladder

- Reduction of cancer proven by ultrasound and cystoscopy
 - Small red spot is visible on cystoscopy, no tumour
 - Abnormal cells on urine cytology persist, not clearly identified as cancer
 - White cells in urine, no infection
 - Asymptomatic, remains on LDN for > 1.5 yrs.
- 

Case 5 – colon cancer

- 53 year old male with cancer of the sigmoid colon
 - History of ulcerative colitis, cancer diagnosed due to routine investigation of rectal bleeding
 - Tumour seen on colonoscopy
 - Localized disease, patient refused surgery due to fear of complications
 - Started LDN + HonoPure to help sleep + reduce anxiety
- 

Case 5 – colon cancer

- CEA was increasing pre-LDN
 - Patient noted improvement in colitis symptoms within weeks of starting LDN (less cramps, diarrhea)
 - CEA began to fall after 4 mo. of LDN therapy
 - Checked monthly:
 - 9.3 - 8.0 - 7.1 - 6.1 - 6
- 

Case 5 – colon cancer

- CEA stabilized between 6 and 7 (normal < 5)
- Repeat colonoscopy confirms no disease progression
- On LDN therapy for over 1 year, still refuses surgery



Case 6 - Published

Long-Term Remission of Adenoid Cystic Tongue Carcinoma with Low Dose Naltrexone and Vitamin D3 – A Case Report

Akbar Khan

Medical Director, Medicor Cancer Centres Inc. 4576 Yonge St., Suite 301 Toronto, ON M2N 6N4, Canada.

Abstract

Naltrexone (ReVia[®]) is a long-acting oral pure opiate antagonist which is approved for the treatment of alcohol addiction as a 50mg per day tablet. The mechanism of action is complete opiate blockade, which removes the pleasure sensation derived from drinking alcohol (created by endorphins). Low Dose Naltrexone ("LDN") in the range of 3-4.5 mg per day has been shown to have the opposite effect – brief opiate receptor blockade with resulting upregulation of endogenous opiate production. Through the work of Bihari and Zagon, it has been determined that the level of the endogenous opiate methionine-enkephalin is increased by LDN. Met-enkephalin is involved in regulating cell proliferation and can inhibit cancer cell growth in multiple cell lines. Increased met-enkephalin levels created by LDN thus have the potential to inhibit cancer growth in humans. Phase II human trials of met-enkephalin, case reports published by Berkson and Rubin, and the clinical experience of Bihari confirmed the potential role of LDN in treating pancreatic and other cancers. However, large scale trials are lacking and are unlikely to be funded given the current non-proprietary status of naltrexone. A case report is presented of successful treatment of adenoid cystic carcinoma as further evidence of LDN's potential as a unique non-toxic cancer therapy.

Key Words: Naltrexone, Cancer, Adenoid cystic, Vitamin D


Introduction

Naltrexone (ReVia[®]) is a long-acting oral pure opiate antagonist which is approved for the treatment of alcohol addiction in 50mg per day dosing [1]. The mechanism of action is complete opiate blockade, which removes the pleasure sensation derived from drinking alcohol (created by endorphins). Dr. Bernard Bihari, a neurologist who practiced in New York, discovered that naltrexone when used in much


Case Presentation

A 58 year old male (Mr. Michel Charest from Montréal, Québec) presented to his family doctor with new swallowing problems, hemoptysis and nausea. There was a history of smoking 1/2 pack of cigarettes per day for about 15 years, alcohol intake of 2 standard drinks per day, high cholesterol and a remote history of jaundice. The only medication taken was atorvastatin. The patient was found to have adenoid cystic carcinoma of the tongue.

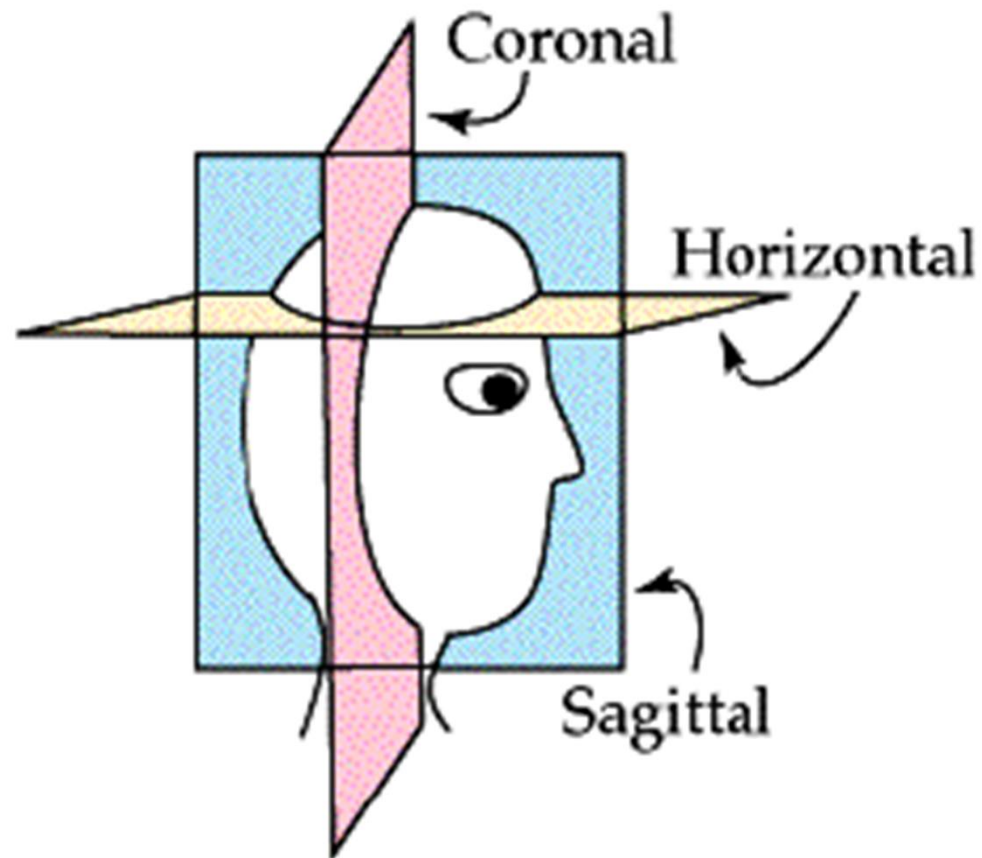
Case 6 – ACC tongue

- 60 year old male, adenoid cystic cancer at base of tongue, no node mets, ~3cm dia
 - Told to have radical surgery, glossectomy + laryngectomy
 - Patient refused due to poor expected Quality of Life (Q.O.L) post-op
 - Chose LDN over possibly curative surgery
- 

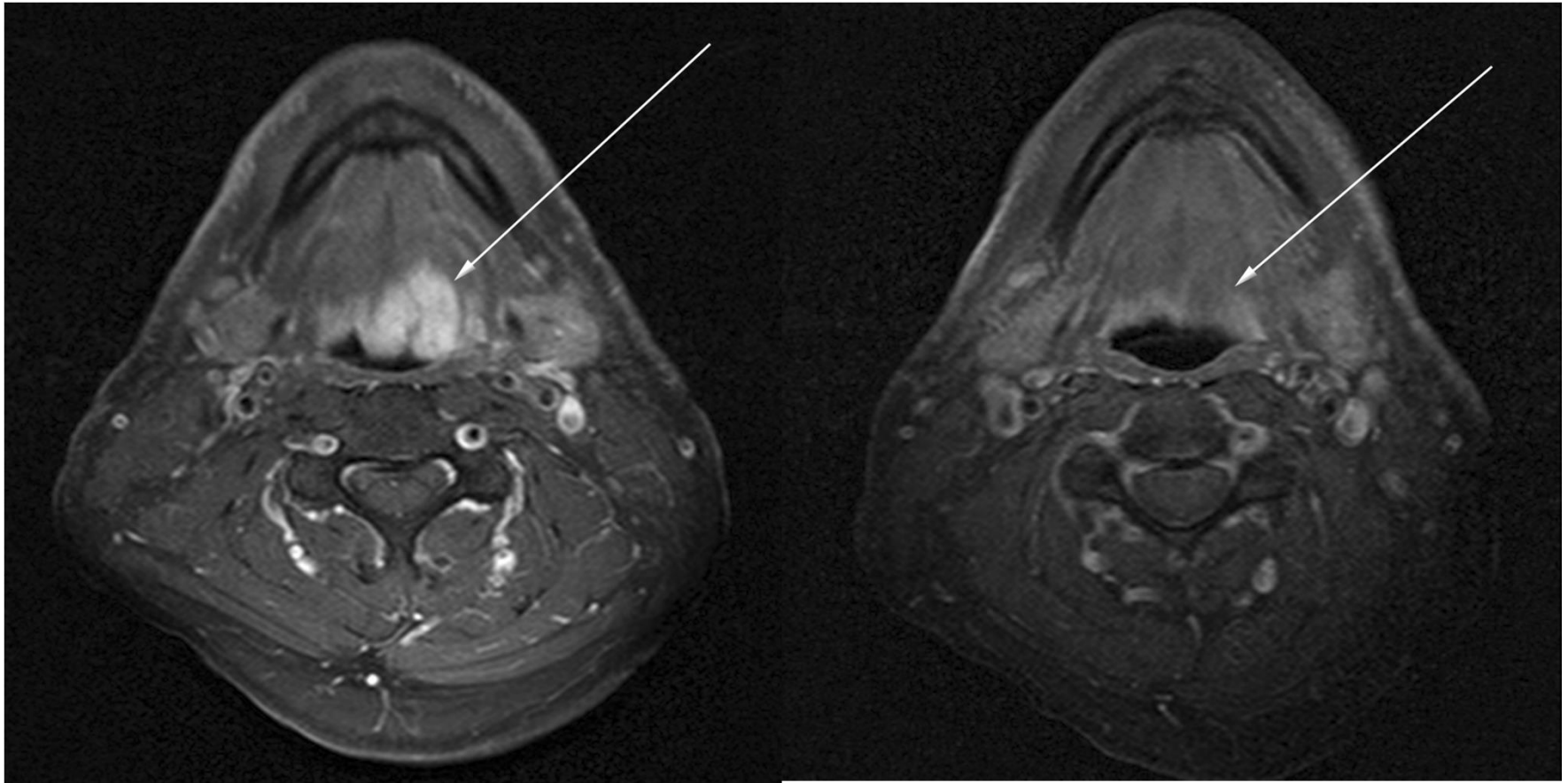
Case 6 – ACC tongue

- Started LDN 3mg at bedtime
 - Added vitamin D 10,000U per day
 - Increased LDN to 4.5mg at bedtime
 - No side effects
 - Mass stabilized over subsequent months, then gradual regression
 - Vitamin D decr to 5,000U per day (level high)
 - MRI after 2 years – complete remission
- 


Case 6 - MRI



Case 6 - MRI




Case 6 – ACC tongue

- Patient remains in complete remission **over 5 years** after the start of LDN therapy
 - Continues to take just LDN and vitamin D
 - Full publication in the journal Oral Health and Dental Management can be viewed on our website: www.medicorcancer.com
- 


LDN as Cancer Prevention?

- Chronic inflammation plays a role in the development of cancer


Examples:

- Higher risk of colon cancer with inflammatory bowel disease (Crohn's/colitis)
 - Higher risk of bladder cancer due to chronic inflammation from parasite *Schistosoma*
- 

LDN as Cancer Prevention?

- Higher risk of liver cancer with chronic hepatitis
 - Higher risk of esophageal cancer with chronic acid reflux causing chronic esophageal inflammation
 - Chronic *H. pylori* infection / inflammation increases gastric cancer risk
 - Chronic pancreatitis and pancreatic cancer
- 

LDN as Cancer Prevention?


- LDN reduces harmful inflammation
 - Chronic inflammation is associated with increased cancer risk
 - Therefore chronic use of LDN in inflammatory conditions may reduce cancer risk
 - Theoretical, no human prevention data yet
 - Study to prove would be costly, but LDN is cheap and safe!
- 

LDN as Cancer Prevention?

Low-Dose Naltrexone for Disease Prevention and Quality of Life

Med Hypotheses. 2009 Mar;72(3):333-7. PMID: 19041189

“Accumulating evidence suggests that LDN can promote health supporting immune-modulation which may reduce various oncogenic and inflammatory autoimmune processes.”




LDN as Cancer Prevention?

The Use of Low-Dose Naltrexone (LDN) as a Novel Anti-Inflammatory Treatment for Chronic Pain

Clin Rheumatol. 2014 Apr;33(4):451-9 PMID: 24526250

“We review the evidence that LDN may operate as a novel anti-inflammatory agent in the central nervous system, via action on microglial cells.”




LDN as Cancer Prevention?

Opioid growth factor and low-dose naltrexone impair central nervous system infiltration by CD4 + T lymphocytes in established EAE, a model of multiple sclerosis.

Exp Biol Med (Maywood). 2016 Jan;241(1):71-8 PMID: 26202376

“CNS-infiltrating CD4(+) T cells are diminished with exogenous OGF or intermittent blockade with LDN administration.”




LDN as Cancer Prevention?


Fibromyalgia Symptoms Are Reduced by Low-Dose Naltrexone: A Pilot Study

Pain Med. 2009 May-Jun;10(4):663-72. PMID: 19453963

“Individuals with higher sedimentation rates (indicating general inflammatory processes) had the greatest reduction of symptoms in response to low-dose naltrexone.”



LDN Summary

- LDN is best used for cases of cancer with low disease burden, prognosis > 3 months (our experience)
 - LDN takes time to work (allow at least 3 mo.)
 - LDN is more appropriate for low grade / slow growing cancers
 - LDN is useful for elderly patients with cancer who may not tolerate other drugs
 - Honokiol is a nice adjunct to LDN
- 

Final Message

- There are many non-toxic cancer therapies, LDN is one of the gentlest and safest!
- Help spread the word to help others!
- Inform and educate your doctor:

Present the published research and case reports!



www.prevent-cancer.ca


processes) had the greatest reduction of symptoms in response to low-dose naltrexone."



Endogenous Opioid Inhibition of Proliferation of T and B Cell Subpopulations in Response to Immunization for Experimental Autoimmune Encephalomyelitis

"OGF or LDN repress proliferation of CD4+ and CD8+T cells and B220+ B lymphocytes in the spleen and lymph nodes of immunized mice within a week of immunization."

"These data provide novel mechanistic pathways underlying the efficacy of OGF and LDN therapy for MS."



Long-Term Remission of Adenoid Cystic Tongue Carcinoma with Low Dose Naltrexone and Vitamin D3 – A Case Report

"At the time of this writing, the patient has been re-assessed by the otolaryngologist who

67% had improved with mild disease activity...at the end of the study. Systemic and social quality of life improved with naltrexone treatment (p=0.035)."



Reversal of Signs and Symptoms of a B-Cell Lymphoma in a Patient Using Only Low-Dose Naltrexone

"We believe that by the mechanisms presented herein, LDN demonstrates significant potential to increase disease-free as well as overall survival in people with FL [follicular lymphoma]."

medical hypotheses

Low-Dose Naltrexone for Disease Prevention and Quality of Life

"Accumulating evidence suggests that LDN can promote health supporting immune-modulation which may reduce various oncogenic and inflammatory autoimmune processes."

"...it may also have a role in promoting stress resilience, exercise, social bonding, and

arthritis, polymyalgia rheumatica, and lupus, may benefit from LDN."

MULTIPLE SCLEROSIS JOURNAL

Formerly Multiple Sclerosis

A Pilot Trial of Low-Dose Naltrexone in Primary Progressive Multiple Sclerosis

"A significant reduction of spasticity was measured at the end of the trial."

"Our data clearly indicate that LDN is safe and well tolerated in patients with PPMS."



Revisiting the ALA/N (a-Lipoic Acid/Low- Dose Naltrexone) Protocol for People With Metastatic and Nonmetastatic Pancreatic Cancer: A Report of 3 New Cases

[Patient #1] GB was declared to be in radiological remission by PET surveillance... At the time of this writing, 39 months after her diagnosis, GB continues with her treatment plan and has no signs of pancreatic disease.[Patient #2] "...6 months following the initiation of therapy, her PET scan failed to demonstrate disease

www.medicorcancer.com
www.prevent-cancer.ca

THANK YOU!

