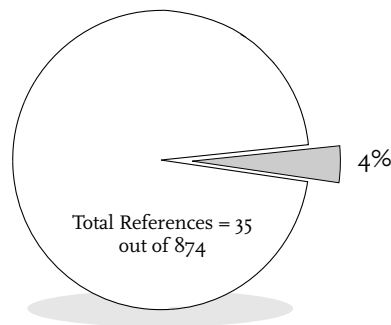


5. Remission of Neoplasms of the Female Breast



Remission of Neoplasms of the Female Breast



References in Chapter Five = 35
References in Part One = 874

Breast cancer affects women more than any other malignant neoplasm. According to the World Health Organization Statistics Quarterly report in 1988, one in 11 women in industrialized countries will develop breast cancer. It was the cause of death of 570,000 women worldwide in 1980.

It is estimated that over 10% of the women in the United States would be diagnosed with breast cancer in 1991 (175,000 women), and new breast cancer cases comprise 32% of all cases of cancer reported in American women. It is estimated that 44,500 American women will die of breast cancer in 1991; 18.4% of all cancer deaths in women (Cancer Statistics, 1991, a publication of the American Cancer Society).

The relative five-year survival rates by race for breast cancer for the years 1960-1986 are presented in Table One. The histological stage distribution and five-year relative survival rates by race are presented in Table Two.

Table One: Five-Year Relative Survival Trends for Breast Cancer By Race†

Years of Diagnosis	White Females	Black Females
1960-1963	63%	46%
1970-1973	68%	51%
1974-1976	75%	63%
1977-1980	75%	63%
1981-1986	78%	64%

† adapted from Catherine C. Boring, Teresa S. Squires, and Tony Tong, "Cancer Statistics, 1991," *CA-A Cancer Journal for Clinicians* 41(1), January/February 1991, 36.

Table Two: Histological Stage Distribution and Five-Year Relative Survival Rates by Race for Breast Cancer††

	White Females		Black Females	
	Age < 50	Age 50+	Age < 50	Age 50+
Distribution (%)				
Localized	50%	49%	44%	39%
Regional	43%	39%	45%	44%
Distant	4%	8%	7%	13%
5-Year Survival (%)				
Localized	89%	92%	84%	88%
Regional	69%	70%	56%	56%
Distant	22%	18%	18%	13%

†† adapted from Cancer Statistic Review 1973-1987, Lynn A. Gloeckler Ries, Benjamin F. Hankey, and Brenda K. Edwards, editors, published by U. S. Department of Health and Human Services, IV. 24 & IV. 30.

Chapter 5 contains 35 references, 22 of which are annotated with summaries. Some annotated references also contain 1 or more case reports. Thirteen supplemental references are included as additional documentation. Full text of 22 case reports is presented (8.5% of the 258 case reports in Part One).

A comparative analysis of cases reported in previous literature reviews is presented in Table Three.

Table Three: Comparison Between Other Major Literature Reviews of Cases of Spontaneous Regression of Neoplasms of the Female Breast

Tumor Site	Rohdenburg (1918) (N=185)	Fauvet (1960) (N=192)	Boyd (1966) (N=97)	Everson (1966) (N=182)	Challis (1990) (N=505)
Breast Cancer	39	16	15	6	22

Neoplasms of the Female Breast

A Case of Carcinoma of the Breast, vs Erysipelas and Arsenic

MOHR C

North American Journal of Homeopathy 3: 1888; 700-702

Extracted Summary

A case of regression of breast carcinoma is reported. Some of the interesting points about this case are the unusual age of the patient when the growth was first noticed: 83; the relief of pain and other subjective symptoms by the selected remedies, conium, belladonna, and lachesis; the rapid disappearance of all signs of a malignant growth (except the cicatrix) and the attendant cachexia, on the supervention of an erysipelas infection; the marked amelioration of the symptoms of the erysipelas from the arsenicum; the rapid repair of a fractured arm, occurring so late in life and so soon after the disappearance of the neoplasm.

The author states that he is “not quite satisfied that the erysipelas alone cured the cancer; the arsenicum may have had something to do with the result. [That the disease was a carcinoma] I have not the least doubt, although I must admit that no microscopic examination of the tissues had been made at any time; but the history of the growth and the macroscopic appearances were so marked in favor of carcinoma that I deemed the microscopic test unnecessary; and with my diagnosis two experts agreed.”

SELECTED CASE REPORT

On July 23rd, 1886, I was consulted by Mrs. E.M.H., a widow, age 83, about a lump she had noticed for an indefinite time in the left mamma. Occasionally she had suffered some pain, at infrequent intervals, but latterly the pain recurred oftener and was more persistent. Except the lump and pains, and a vertigo, experienced most after first lying down, and when rising from a sitting position, or when turning the head suddenly, her health was good, and she was a woman who had reared a family, had been very active, and scarcely ever employed a physician.

An examination of the breast revealed a somewhat flattened tumor almost centrally located, about the size of a hen's egg, hard and inelastic, and presenting irregularities. The tumor was adherent to the skin, there was slight dimpling, and fixation of the nipple, which I could not draw forward. I could not detect any glandular involvement in the adjacent lymphatics, and despite her age, because her general health was good, I advised the extirpation of the growth. The patient and her family objected to any operative measures, and I was asked to treat the case purely medicinally. I therefore prescribed conium, *ix*, a drop mixed in twelve teaspoonfuls of water, and given in two-teaspoonful doses every three hours for one week. Improvement in the vertigo was soon manifest and the mammary pains were less severe at the end of a week. I then stopped medication, but repeated my prescription

of conium, *ix*, on August 4th and 17th, 1886, and on January 1st and May 27th, 1887, always with the relief of the pains and the vertigo. The tumor, however, continued to grow. Retraction of the nipple ensued, the adhesion to the skin became more marked, and the vascular channels were occluded, as indicated by discoloration of the skin and enlarged veins.

On July 23d, 1887, an examination showed a still greater area of infiltration, with involvement of the axillary glands, and in the neighborhood of the original growth small but firm indurations were felt and seen. The neoplasm was now easily recognized as a large projecting tuber elevating the skin. At this time she suffered from intense pains, shooting and lancinating in character, going and coming quite unexpectedly, and robbing her of rest and sleep. Belladonna I, in drop doses, on sugar of milk, was then administered, and I had the satisfaction of again witnessing relief. From this time until October 15th, 1887, she required no other medicine, at least I gave her none, although ulceration of the skin had taken place, and the fissure had gradually widened and deepened, until a shallow excavation, with indurated edges and a ragged base, was anything but a sightly object. As she had suffered little pain, lost little sleep, and was fairly active for so old a woman, I preferred to resort to earth dressings to absorb the thin, ichorous and offensive discharge from the ulcer, and to keep up her strength as well as possible by

systematic and careful feeding. A few doses of lachesis, 30 were given on October 15th, because latterly when she experienced pain it was always after sleep.

The patient, however, grew more and more feeble, lost appetite, was compelled to seek her bed, from which it was supposed she would never arise, and towards the latter part of November, 1887, general infection was pronounced; there were present all the phenomena of a cancer cachexia. This state continued until December 19th, 1887, when I was summoned to witness the patient extremely restless, complaining of chilliness and much fever, frequently demanding water, of which she would only take a sip or two, and complaining of most severe burning pain in her breast, the worst she had ever experienced. The symptoms had set in after midnight and continued to grow in severity, attended by delirium, until eight A.M., when I reached her bedside.

An examination of the breast at this time revealed a complete dryness of the ulcerated excavation, and a distinct line of redness extending outward from the edge of the ulcer about an inch, with a sharp outer border. Not only was the axilla filled with enlarged and indurated lymphatics at this time, but the supraclavicular glands were prominent in the now emaciated patient. The tongue was dry and the pulse accelerated, the temperature variable, and the patient's face expressing great anxiety. I could do no better than prescribe arsenicum 3x, trit., of which she received one grain every two hours.

If there was any question of diagnosis as to the sudden inflammatory symptoms on the morning of December 19th, there was none on the following day, for

the inflammation of the skin had spread rapidly, extending upwards to the neck and downwards to near the crest of the ilium. The inflamed portion of the skin was somewhat raised, with a sharply defined irregular border, intensely red, hard to the touch, but pitting slightly on pressure from displacement of serous infiltration beneath. It was undoubtedly erysipelas.

Under the arsenicum the febrile symptoms abated, the severe burning became less, sleep was induced, and while the thirst lessened, the appetite, which had entirely disappeared, improved. I next noticed a rapid disappearance of the enlarged lymphatics of the supra-clavicular and axillary regions, and within ten days they were scarcely perceptible. Then the cancerous mass itself began to grow smaller; the ulcerated excavation became more and more dry and less offensive, and on January 22d, 1888, nothing remained of the neoplasm but a puckered cicatrix, about two inches long and one-half inch wide. In the meantime the general health improved marvelously, too; the appetite became excellent, food was readily digested and assimilated, she fleshed up, slept well, and suffered very little discomfort in any way. Indeed, so thoroughly restored was she, that, despite a fracture of the left humerus, induced by a fall while getting out of bed on the morning of April 5th, 1888, repair, under surgical treatment, was rapid, and on April 29th it was possible to remove all dressings and to begin motion at the shoulder and elbow joints.

At the present time she has complete use of the arm, is in good flesh, goes about the house as freely as her impaired vision from senile cataract will permit, and for one in her 86th year is in a fairly good condition.

A Case of Spontaneous Disappearance of Secondary Cancerous Growths

GOULD AP

Clinical Society. Transactions 30: 1897; 205-208

Extracted Summary

A case is reported in which, after three operations for breast cancer; the first operation removing the left breast, the second the axillary glands, and the third secondary lumps in the operation scars; secondary growths occurred in both breasts which were not removed. These growths along with secondary metastases in the lung and left femur disappeared without any further treatment.

SELECTED CASE REPORT

A single woman, M. C., a sick nurse, was until recently an inmate of one of the special cancer wards of the Middlesex Hospital. She states that in 1885 she was struck on the left breast with an umbrella. In 1888 she noticed a small lump in the breast; this slowly enlarged, and in May 1890, she was admitted into the London Temperance Hospital under the care of Dr. Collins, who diagnosed the case as scirrhus mammae, and excised the breast. The tumour was examined microscopically, and pronounced by two competent observers to be "typical

scirrhus cancer." Both the tumour itself and the microscopical sections of it have been mislaid.

In July 1892, she noticed a lump in the left axilla. She returned to the hospital, and Dr. Collins removed the axillary glands.

In February 1894, the patient noticed some lumps in the neighbourhood of the scar of the first operation, and also a lump above the right breast. For these lumps a third operation was undertaken by Dr. Collins, all the nodules being excised.

In December 1894, she was again admitted to the Temperance Hospital, and was found to have several recurrent nodules round the scar and considerable dyspnoea. She was told that no further operation was advisable, and that she ought to seek admission to the cancer wards of Middlesex Hospital.

On January 17, 1895, she was admitted into Laffan Ward under the care of Mr. Lawson. She was then forty-three years of age, and stated that for the past twelve months she had been getting thinner and suffering in her general health. Around the scar on the left side of her chest were numerous firm tubercles involving the skin and subcutaneous tissue, and in the left axilla were several hard, enlarged glands. Above the right breast was a linear scar two inches long, in the centre of which was a hard nodule, and in the right axilla several hard enlarged glands were felt. Enlarged glands were also present above each clavicle. The patient's only complaint was of dyspnoea, which was paroxysmal in character, and prevented her lying down. There was dulness over the base of the right lung, and numerous sonorous and groaning rhonchi were heard over both lungs. She continued in a very grave state with great dyspnoea and abundant expectoration for some months; then in the summer of 1895 she got somewhat better, but was worse again in the winter of 1895-6.

I saw her first in March, 1896. She was then unable to lie down in bed, was cyanosed, suffered much from dyspnoea, cough, and expectoration, and the sputum had recently contained blood on two occasions. There were many hard nodules in the skin of the left side of the chest grouped around the scar, and one larger nodule in the scar above the right breast. Masses of enlarged glands were felt in each axilla and above each clavicle. There was dulness over the right lung below the spine of the scapula. The liver could not be felt enlarged. She told me that she was suffering much pain in the left thigh, and on examination I found considerable deformity present. The limb was an inch shorter than its fellow; the great trochanter was raised above Nélaton's line, and just below the trochanter the bone was greatly enlarged. In addition to the external recurrent cancerous growths I believed that M.C. had secondary cancerous growths in the right lung and in the left femur, and I expected her death in a very short time.

A few weeks later the patient passed into my care, and on June 15, 1896, I examined M.C. again, and found one tiny nodule in the skin above the left scar. The right scar was keloid, and thicker in the centre. There were no enlarged glands to be felt in either axilla or above either clavicle. The patient's general condition was much better;

she was no longer troubled with dyspnoea, she could lie down in bed, and the dulness of the right chest had disappeared except at the extreme base behind. (Dr. Fowler kindly saw her on this day, and expressed the opinion that the signs pointed to slight pleural thickening.) The left thigh was deformed as before, but was less painful.

Since this she had steadily progressed. She had gained flesh, has a good colour, and enjoys life. She walks with a limp, but can rest her weight upon the left leg. The limb is one and a half inches shorter than the right, the trochanter is raised, and there is an acute curve forwards in the shaft of the femur just below the trochanter, but the bone is not notably enlarged. The scar on the left side is quite soft and supple, and the skin around it is absolutely free from all nodules or signs of cancerous growths. The right scar is still rather keloid, and in its centre is thicker than elsewhere. There are no enlarged glands in either axilla or the neck.

No special treatment was employed; during her stay in the hospital she took various drugs at different times in the hope of alleviating the various symptoms; chloroform, morphia, ether, pine oil inhalations, creosote, bromide of ammonia, bismuth and hydrocyanic acid, phenacetin, quinine, antipyrin, caffeine, salicylate of soda, iodide of potassium, iron and senega.

It is perhaps worthy of note that the last time she menstruated was at the end of January 1895.

It is to be regretted that the microscopical specimen of the primary growth has been mislaid, but apart from the fact that it was pronounced to be typical scirrhus by competent observers, we cannot question that the clinical history and course of the disease in M.C. is that of carcinoma. I may mention that so experienced an observer as Mr. Lawson had no doubt as to the nature of the malady this patient suffered from while under his care.

It is difficult, if not impossible, to account for the change that has occurred in this patient's femur in any other way than by the development of a tumour in the bone, destroying its rigidity and then itself undergoing absorption, and new bone forming to consolidate the weakened and deformed femur. It is noteworthy that the history points to the primary growth starting at the age of thirty-seven, and then running a rather slow course; this is contrary to what we generally observe, that the earlier in life carcinoma arises, the more rapid and malignant is its course. The case is one of such interest and importance that, although incomplete, it seems worthy of being shown to this Society.

The Medical Aspects of Carcinoma of the Breast, with a Note on the Spontaneous Disappearance of Secondary Growths

OSLER W

American Medicine: April 6 1901; 17-19; 63-66

Extracted Summary

The consulting physician sees mammary cancer at two stages of its progress. Dreading the surgeon, and hoping against hope, a number of women prefer to come to him at the first detection of a tumor. But these form a small fraction of the cases. A large majority are the unhappy victims of the internal metastases after operation. For some years I have been interested in this class of cases, and have collected material bearing upon the question of these late, and more strictly medical, manifestations of the disease.

In this paper, fourteen cases of carcinoma of the breast are reported in which there were secondary growths and in some cases the secondary growths spontaneously disappeared.

SELECTED CASE REPORT

Case 5. Tumor in right breast noticed January 1897; operation November 1897, scirrhus; good health for a year; in September 1898, pains in the back and down the legs; recurrence in the right eye; gradual increase of the pains in the legs; orthopnea; emaciation; recurrence in the left breast; tumor mass on sternum; effusion in right pleura. After remaining for months in a desperate condition, gradual improvement; disappearance of tumor on sternum; improvement in vision of the right eye; throughout 1900 persistence of pains to slight extent, but general improvement.

Miss X., aged 31, consulted me October 6, 1897 for a lump and pain in the right breast, which had been first noticed in January. She had had a fall from her bicycle in November, and to it the trouble was attributed. In a few weeks she entered the Johns Hopkins Hospital, where Dr. Halsted did a most extensive radical operation. The glands in the axilla were much involved; to one of them the axillary vein was adherent, and part of it had to be excised. The case is No. 7943 in the surgical histories of the hospital. The histological diagnosis was scirrhus. The patient improved, and returned to her home in a few weeks.

On September 24, 1898, she returned complaining of difficulty of vision in the right eye and pains in the back and down the legs. She looked well, but I was naturally apprehensive about the condition, and, as she and her mother were on their way to Philadelphia to visit the father, who was under the care of Dr. de Schweinitz, I asked them to let Dr. de Schweinitz examine the eyes carefully. The following day he reported to me that there was a tumor in the right eye. He had not been told about the operation, and of course when informed he recognized the condition at once as a secondary carcinoma. There was no local recurrence in the scar.

Winter of 1898-1899: I saw the patient again on November 31. She had shooting pains about the sides,

cough, and pains in the legs. There was no pain in the right eye, the vision in which had become progressively worse. About Christmas she became confined to her bed, and the pains were so severe that she had to take morphia. She passed the winter in great distress, the condition becoming steadily aggravated. I saw her twice, and in May her condition seemed really desperate. She had become very thin; there were constant orthopnea, and paroxysms of very severe pain at night, so that the morphia had to be increased to 2 grains at a dose. The emaciation was extreme. The pains were chiefly down the legs and around the sides. There was no local recurrence, but a lump had appeared in the left breast. There was tenderness about the fourth and fifth dorsal spines. About the junction of the manubrium with the gladiolus there was a distinct tumor, which was very tender, and which looked like a new growth in the bone. There was an extensive pleural effusion on the right side.

I left for England shortly afterwards, and, of course, did not expect to find her alive on my return. She gradually improved through the summer, the dyspnea lessened, the pains became less intense, and toward October she began to get up and move about.

Winter of 1899-1900: She had on the whole a gaining winter. The pains were less intense, and the morphia was reduced to about a grain 3 times a day. She improved in color, gained in weight, and was able to walk about the house and about the grounds. A remarkable change had taken place in her back. There was a distinct prominence about the fourth and fifth dorsal spines, the back was stiff, and she had a marked stoop. The knee jerks were a little exaggerated. The pains down the legs, which were formerly so excruciating, had almost entirely disappeared. The tumor on the sternum had disappeared. There were no local recurrences. The tumor in the left breast had not increased in size. The most remarkable thing was the

progressive improvement in the vision of the right eye, which had been almost entirely lost. She could now recognize faces and even see large type.

During October of 1900 I saw this patient twice. She had improved in every way. She was able to do very much more. She drove a mile and a half to the station to meet me, and drove me to the station on my return. She was still very thin, but her appetite was fairly good, her color is

good, she walks stiffly, but gets about with much more comfort than formerly.

I saw her again on December 9, 1900. She had had a little more pain, particularly in the right leg, the sight had not been so good, and on the whole she had been failing somewhat, though she was still able to be up and about, and her appetite was fairly good. There was no local recurrence, and there was no increase in the tumor in the left breast.

A Case That Seems to Suggest a Clue to the Possible Solution of the Cancer Problem

MACKAY CG

British Medical Journal 2: 1907; 138

Extracted Summary

A case of metastatic breast cancer is reported in which the author postulates that the ascites in the pleural cavity in some way caused a spontaneous regression of the metastases. He asks "What is the meaning underlying this? What really took place? The patient had been in a half-starving condition—starved of food and of water—a state most favourable to the absorption of a thoracic exudation. When absorption took place pressure was taken off the oesophagus and swallowing became possible. The same cause relieved the lungs, and the respiration fell to 24. Improvement, not only general, but also local, coincided exactly in point of time with the disappearance of fluid from the chest.

"How did this affect the cancerous tumour? Let us consider the facts as they appear, and then endeavor to account for them. The fluid (serum) had been suddenly, rapidly, and in considerable quantity taken into the system. It thus came into contact with a malignant growth which at that moment was overwhelmingly master of the situation. Be the cause what it may, the sequel was that thenceforward the growth not only ceased to advance, but actually withered and steadily parted with the most marked features which constitute its character. There was hardly escape from the conclusion that these two things stood related to each other as cause and effect. In other words, does not this mean that serum causes a tumour to retrograde?"

SELECTED CASE REPORT

Miss X.Y., aged 37, had a typical mammary scirrhus in the autumn of 1904. I first saw the case early in October and diagnosed carcinoma. Some weeks later the case was seen by my friend Dr. Bruce, of Dingwall, who was of the same opinion. She immediately went to Edinburgh and entered the Deaconess Hospital, where the tumour was removed by Mr. Alexis Thomson. Thirteen months after the disease recurred and in such a form as to render a second operation inadmissible and x-ray treatment was recommended and used for some time. The other breast became involved, a troublesome cough came on, and later pleurisy, first in one side and then in the other.

Since this paper was read I have received, by the kindness of Mr. Thomson, a copy of the hospital report, from which I have extracted the following: Miss —, 37 years of age, admitted Deaconess (Hospital) November 1904. She had noticed a lump in the right breast since April,

and had seen Dr. MacKay, of Lochcarron, and Dr. Bruce, of Dingwall. She was in very good health.

There was a circumscribed cancer in the outer quadrant of the right breast, adherent to the skin, and nothing was to be felt in the axilla. The complete operation was performed on November 4th, 1904; the axillary glands were infected but there was nothing at the operation to show that this case was specially unfavourable. She made a good recovery and went home.

The microscopical diagnosis was the common form of scirrhus cancer. On January 9th, 1905, she showed herself again. There were small fixed nodules in the scar, a large fixed one below the clavicle, and there was bulging of the sternum. As it was quite out of the question to operate she was put on a course of the x-rays, and these were pushed to the extent of reddening and scaling of the skin. The result was that the progress of the disease seemed to be arrested.

She returned to the hospital in August 1906, for another course of x-rays. The disease had again made progress after the manner observed in recurrent cancer of the breast. She had an irritating cough, which was regarded as being due to pressure on the recurrent laryngeal nerve, and there was a marked degree of breathlessness and dullness over the pleural cavity on both sides.

On the first occasion on which she was tapped 40 ounces of blood stained fluid were drawn from the left pleural cavity, and 10 ounces of similar fluid from the right; after the tapping there was dullness up to the lower angle of the scapula on both sides, and there was also dullness of the right apex. A fortnight later 28 ounces of blood-stained fluid were drawn from the left pleura. The breathlessness returned. An attempt was made to tap the left pleural cavity, but only a few ounces of blood-stained fluid were drawn off. It was inferred that the dullness was now mostly due to thickening of the pleura and consolidation of the lung, due to metastasis of the cancer. She gradually failed in health and made up her mind to go home (November 8th, 1906). In his covering note Mr. Thomson says: "This diagnosis of cancer was based on the usual complete microscopical examination of the tumour of the breast and of the glands. There is absolutely no doubt of the disease being cancer."

The patient came home from the hospital on November 8th last in a hopeless condition, and for several weeks in December her state was one of semi-collapse. The disease then was evident by a deep blue discoloration over the whole front of the chest from the clavicles to a line a little above the level of the upper margin of the liver. The left breast was of great size and hard. The left axilla was obliterated, filled with malignant growth. In the right axilla matters were much the same, though not quite to the same extent. Both sides of the chest contained fluid almost to the clavicles. The respiration was 44. Swallowing anything, even a teaspoonful of water, was difficult, and sometimes impossible.

This state continued up to and including December 27th. On the morning of December 28th, it was found that the condition had entirely altered. She was much better

and felt comparatively comfortable. She could swallow quite easily. The respiration had fallen from 44 to 24. The fluid in the chest was in greater part gone. She gradually took food in fairly good quantity and improved in every way. Still more remarkable was the fact that the seat of the local disease (the front of the chest) gradually underwent a change for the better quite as great as in the general condition. In its whole extent the deep purple discoloration became very markedly lighter. In some places the skin regained its original whiteness and where it had been tense and shining it became at first wrinkled and then flaccid.

The diseased parts that had not been treated with the x-rays have undergone an extraordinary change. On the left side, the breast, which had grown to a large size and felt hard, has absolutely disappeared with the exception of a circular flat disc the size of a sixpence, fully 1/8th of an inch thick, brown-yellow, and of horny consistence and appearance, which occupies the place where the nipple had been. There is no trace of a gland and where it had been the skin is flat and close to the ribs. The left axilla, which was full of cancerous growth, is now a cavity into which I can place my closed hand. In the right axilla there is a similar result.

The space where the right breast, which had been excised, had been and the parts adjacent had been subjected repeatedly to x-ray treatment, and here the improvement, though quite as decided, has gone on at a slower pace. Though there is healthy action, the tissues seem to be in a semi-paralysed state. The x-ray has not been elective in action. It has affected the disease and the healthy tissue in equal degree.

The cough, which had never been absent for ten months, ceased on a certain day, January 6th, and has not been heard once since. Up to this date, February 11th, there had been steady improvement in everyway. Morphine, of which 1 1/2 grains was the routine dose for some time, was gradually reduced, and lately stopped altogether. For the last week the only anodyne needed was suphonal; 5 grains at night.

Treatment of Carcinoma with the Body Fluids of a Recovered Case

A Preliminary Communication

HODENPYL E

Medical Record 77: 1910; 359-360

Extracted Summary

This preliminary communication is made, first, in order that the attention of the profession may be called to the possible significance of body fluids from the rare cases of those who have recovered or are recovering from carcinoma; second, to correct the false impressions which may have been conveyed by the premature and unauthorized news items in the daily press; and, finally, to secure an opportunity to remind physicians practically interested in this study, that the urgency for this

treatment, of hopeless inoperable cases, is hardly just, either to these patients themselves or to a method from which it is hoped to secure new resources and new light through deliberate and reasonable tests.

It is not my purpose to announce at this time a new cure for cancer, but to call attention to the remarkable, selective necrotizing effects upon carcinoma cells of the ascitic fluid from a recovered case of carcinoma, wherever in the body of the patient the fluid is introduced.

SELECTED CASE REPORT

About four years ago the writer became interested in a case of carcinoma of the breast in a woman then 37 years of age. The clinical history and the morphology of the tumor were typical of a rapidly growing malignant cancer. In spite of a radical operation, multiple recurrences appeared in the neck and in the primary scar. After the thorough removal of these, secondary growths appeared which were morphologically typical of rapidly growing carcinoma. Still other tumors developed in the neck and breast, which, owing to local complications and the debilitated condition of the patient, were not removed. Later large tumors developed in the liver, which nearly

filled the abdominal cavity, followed by the occurrence of excessive chyloform ascites. The prognosis was unqualifiedly bad and the patient's death seemed imminent.

But, nevertheless, the tumors in the neck and breast gradually dwindled and disappeared. The abdominal tumors gradually grew smaller and became imperceptible, while the liver became smoother and smaller. At length about four years after the first operation the liver is approximately normal in size and position. With the exception of the scars and decreasing emaciation, and extreme chyloform ascites, requiring frequent tapping, there is now no indication of the original disorder.

Disappearance of a Secondary Carcinoma Without Extirpation

LILIENTHAL H

International Journal of Surgery 26: May 1913; 156157

Extracted Summary

A case is presented in which the patient has remained well for many years following the surgical excision of a secondary metastases of breast carcinoma.

In his discussion of this case the author refers to an article by Deaver in the March 19, 1913, issue of the Journal of the American Medical Association, in which Deaver found that, of mammary cancer treated by radical operation, not more than one in five patients is cured. The author comments that "taking the work of the surgical world in general this proportion is doubtless much too high. When we have to deal with recurrences, relapses or metastases in this form of carcinoma the number of actual cures must indeed be very small."

SELECTED CASE REPORT

Mrs. X., 58-years-old, and the mother of five children, had suffered for years with symptoms pointing to cholelithiasis. Although sharp attacks of colic were not a feature of the case, its chronicity and the continual presence of pain and discomfort caused her son, a physician of unusual scientific ability, to urge operation. In addition to the more usual dangers which attend long continued disease of the gallbladder, he had a great and well-founded fear of malignant degeneration from gallstone irritation. Accordingly, the patient entered the Private Pavilion of Mt. Sinai Hospital, and in April 1904, I removed a small gallbladder whose thick walls tightly hugged a few large calculi. The viscus contained no bile.

After convalescence Mrs. X found herself well and

so remained for three years, when I was asked to advise her concerning a tumor of the right mamma. The growth being obviously a carcinoma I performed a radical amputation on July 25, 1907, removing mamma and axillary contents together with the large and small pectoral muscles in one mass.

The operation was a very extensive one, and healing was slow but complete. Dr. F. S. Mandlebaum, pathologist to the hospital, after histological examination, reported "Schirrhous with no lymph-node involvement."

One and one-half years later she again presented herself, calling my attention to a nodule the size of a large filbert just in front of the anterior axillary line at the level of the seventh or eighth rib. The adherent skin cover-

ing the node was a little reddened. The indurated mass could be shifted to a limited degree, but was apparently adherent to the underlying structures, and a few fine rales suggested that the pleura beneath had already been attacked.

With the help of local anesthesia I removed the main portion of the tumor, without, however, invading the ribs or pleura. I felt that radical measures in a case of this kind would probably shorten the life of my patient.

The wound was not closed by suture or otherwise, but was left to granulate, so that its base might be treated by "fulguration." The late Dr. Lustgarten carried this out in several sittings, using a coil spark, the electrode being the graphite point of a lead pencil.

The wound granulated nicely, but I had little confidence in the outlook and so stated to her son, the physician, who at the pathological examination had ascertained the carcinomatous nature of this recurrence. He then undertook the further treatment of the case, employing, under the guidance of Dr. G.L. Rohdenburg, the Gwyer method of hypodermatic injection of thymus gland emulsion.

The wound healed with a resulting soft cicatrix, and the patient has remained well for years with no local relapse or metastasis.

It will be noted that this report is made simply to record a very unusual case, and not to call attention to the cure as a result of any particular form of treatment.

Arrested Development of Cancer

BOYD GA

Colorado Medicine 11: 1914; 162-165

Extracted Summary

A case of arrested development of cancer of the breast with metastases to the liver and intestines is reported. The author discusses the possible connection between regression and the ascitic fluid and mentions the cases and experiments of Hodenpyl, specifically a case of cancer of the breast with many recurrences in which the metastases disappeared. Hodenpyl does not say in his report whether the patient began to improve before any ascitic fluid was withdrawn. But she did improve, and four years after the first operation the tumor in the liver and the tumors in neck and chest had disappeared but the chyloform ascites remained.

Hodenpyl used this ascitic fluid first on mice with implanted and spontaneous tumors. The results noted were marked necrosis and diminution of their size, or a complete disappearance. He next tried the injection of the fluid on man, into the tissue of the tumor, and intravenously. He says, "In all cases the tumors have grown smaller; in some cases disappeared altogether. In no instance has any other tissue in the body other than the tumor shown the least reaction after the injections, nor have any systemic effects been manifest after large venous infusion."

SELECTED CASE REPORT

Mrs. S., aged 48, German, married; one child 12 years old. Only one pregnancy. Father died at age of 72 with cancer of the stomach. Mother and brothers and sisters all living and well. Personal history good.

In December 1908, she noticed a small tumor in the lower inner quadrant of the right breast. It was not painful. It grew slowly and in February, 1911, she began to suffer pain in her back and middorsal region, more intense on left side and much more painful at night.

June 1911, the tumor began to grow rapidly. Dr. Timmons was called in August and on August 19, 1911, I removed the tumor with the pectoral muscles, enlarged lymphatics and vessel sheaths. The tumor consisted of one large cancerous mass at the site first noted and several other nodules in the gland tissue. The liver extended 1 1/2 inches below costal margins.

The recovery of patient was uneventful, with the exception of continued pain in back. Dullness, bronchial

respiration with moist rales appeared in base of left lung. This disappeared in about five weeks. Three weeks after the operation she developed severe constipation, which cleared up but returned in April 1912, necessitating relief.

A thin-walled cyst containing a colloid material was bound to the ileum by a Jackson's membrane. Removal of both gave her complete relief. At this operation the liver was seen to contain numerous cancerous nodules on upper and lower surfaces. The gall bladder and ducts were free. A grave prognosis was given, but the patient improved and was soon doing her own work, which she continued to do until Thanksgiving, 1912. She had not felt well since the latter part of August. December 17, 1912, nine quarts of clear ascitic fluid were removed by trocar. The liver at this time extended to within two inches of pubic arch, and there was marked edema of the lower limbs.

From this time on the trocar was used every five to nine days until the 14th of March, 1913. At the third tap-

ping the fluid was a muddy brown color, due to altered blood in the fluid. This discoloration was slightly noticeable at the next tapping. Again in the latter part of February, there was hemorrhage into the fluid from the trocar wound, which was noticeable at the time as the fluid came bright red after starting clear.

The patient's condition at this time was bad. She was cachetic, weak, bed-ridden; the edema had become general, metastases in all the palpable lymph glands, bone metastases as shown by a diploic growth in the right frontal bone just above the brow, and nodules appearing and disappearing in the scalp; their transient character is due, according to Handley, to the development of the tumor cells without production of tumor stroma, the absence of the stroma leading to their death and absorption. The urine scanty, the patient feeling no desire to empty bladder more than once in 24 hours. She could eat but little and was unable to sleep.

After the last withdrawal of the fluid, March 14, 1913, there was no return of the ascites, the edema disappeared rapidly, the urine increasing in quantity; the general pain and distress subsided, appetite and sleep returned, the metastases melted down until the growth on the forehead became small as a bean and the lymph glands but slightly larger than normal. The patient rallied like a young man from lobar pneumonia. This improvement continued and by May she was doing her own work and looking and feeling well.

In July she visited a sister in Denver and while there did a great deal of sight-seeing, coming home the latter part of the month not feeling so well. In August she began suffering pain in her bones, deep soreness in the tibia, knees and shoulders. The old metastases began to grow and now are almost as large as before her improvement. There is no ascites and the liver is not perceptibly enlarging. I removed a lymph gland from her neck. Dr. Loomis prepared sections, which are here for your inspection. The sections show a rapidly growing cancer. To those of you interested in the cytology of cancer, the theory of Handley as to the life cycle of all cancer aggregates, the role and significance of nuclear changes and cell genesis, and the nuclear cytoplasm relations, in fact the real cancer problem, the sections will have an abundant interest. I regret that the great clinical significance of this and similar cases forbids further discussion of this phase of the question.

For a time the patient recovered as if the usual relation of host and parasite had been reversed and she fattened upon the stored energies of the tumor. She grew rapidly in

strength and flesh and the tumors vanished. While the experimental evidence is against the ascitic fluid having any curative influence, it is hard to divorce in one's mind the sequence of events.

From December 17 to March 14, a period of 86 days, an average of 47 ounces of ascitic fluid collected in her abdomen each day, assuming no absorption. Suddenly the accumulation of fluid ceased and the patient began to improve. The hemorrhages into the abdomen, which occurred in December and February, may have been factors in bringing about the improvement. Autolytic changes in the ascitic fluid may have given rise to protective substances whether in the nature of antibodies, enzymes, cytotoxins, or salts of the metals that, acting upon the tumor cells, may have caused the retrogression noted.

The blood count, made September 23 by Dr. Bortree, shows hemoglobin, 85%, 4,120,000 red cells, 9,000 leucocytes, 65% polys, 10% lymphocytes, small mononuclears 14%, transitional 1%, large monocytes 14%, mast cells 1%. Red cells normal in size and shape, with considerable polychromatophyia. The blood pressure is 132 and the urine normal.

The case is a common one, insofar as it represents the history of cancer of the breast in the lower inner quadrant, with metastases in the liver and intestine, which had occurred before the operation as shown by no local recurrences.

It is remarkable for the rapidity of development of the ascitic fluid, for the degree of exhaustion before improvement and the rapid recovery with sudden cessation of ascites.

I shall not soon forget my feelings when, two weeks after I had been with Dr. Timmons to the home of the patient for the purpose of relieving her ascites that her few remaining days might be as comfortable as we could make them, and listening to her: "How long do you think it will be, Doctor?" and our equally resigned assurance that we did not know, but not very long, and her final reply, "I hope not; I am so tired," she walked into my office, with a triumphant smile and the greeting, "I am getting better, Doctor."

If I had signed her death certificate two weeks before I think the sensation would have been but little less delightfully confounding.

And yet, standing in the presence of the final impending wreck, I feel that nature has flaunted her cure under my eyes and they have been too blind to see.

Cancer of the Breast

Recurrence Thirty-One Years After Operation

STEWARD FJ

British Medical Journal 1: Jan 24 1925; 156

Extracted Summary

The case of an 81-year-old woman is reported in which secondary growths occurred thirty-one years after an operation for breast cancer. There can be little doubt that the subcutaneous nodules and the mediastinal growth were directly connected with the original growth in the breast, and, if this is so, it would appear that carcinoma cells may lay dormant in the tissues for a period of upwards of thirty years, and for all this time give no sign, and then simultaneously, in at least four separate and distinct sites, once more become active.

The author states, "I make no apology for publishing a note of this case owing to its outstanding interest in its bearing on the age-long question, When is cancer cured?"

SELECTED CASE REPORT

Mrs. R., aged 81 years, was operated upon for cancer of the left breast thirty-one years ago by the late Sir Henry Butlin. She had no further trouble until a few months before I saw her when Dr. Bromley discovered three small hard nodules beneath the skin of the left chest in the immediate neighbourhood of the scar of the operation wound. These slowly increased in size. During the past two months some enlargement of the veins over the front of the left chest had appeared, and the patient complained of some degree of breathlessness and of pain in the chest.

When I examined her I found three hard nodules, as Dr. Bromley had observed. These were each about half an inch in diameter, were situated beneath the skin, and were not fixed either to the skin or to the deeper parts. These

nodules were each close to the operation scar and were separated from one another by about an inch and a half. The front of the chest to the inner side of the scar was somewhat prominent, and a few dilated veins were to be seen. There was also some degree of dullness on percussion over the prominent area. The patient was rather breathless and looked ill, but not extremely so. She, however, died the same night.

There can be no reasonable doubt that the superficial nodules were carcinomatous, and that they had appeared quite recently, for Dr. Bromley was satisfied that they were not present much more than two months before my examination. There was certainly also a growth in the mediastinum, which had probably been present for some time, and which presumably caused the patient's death.

Long Freedom from Recurrence After Operation for Cancer of the Breast

BOWLBY A

British Medical Journal 1: Jan 31 1925; 234

Extracted Summary

In the correspondence section of this journal, in response to a case reported by Mr. F. J. Steward, the author relates the case of a woman who developed a recurrence of breast cancer 24 years after surgical removal of the original tumor and axillary glands.

SELECTED CASE REPORT

Some years ago I operated on a case of recurrence twenty-four years after operation. The right breast and the axillary glands were originally removed by Sir Thomas Smith for a typical scirrhus cancer, and I saw the patient with him after an interval of twenty-four years of good health. She had then recently developed a small lump in the skin, two inches below the middle of the right clavicle, and there was also a hard gland above the clavicle. I removed both of these, and the microscope showed

typical breast cancer. A further examination while the patient was anesthetized revealed hard tumours in each ovarian region, and she died within a year with growths in the cervical glands and visceral dissemination. The facts that the recurrence was in the skin of the chest and that it was typical breast cancer leaves no doubt that this was a case of genuine recurrence of the original tumour, and not of an independent new growth originating in breast tissue left behind at the first operation.

Cancer of the Breast Treated Medically

BULKLEY LD

Cancer 2(3): Apr 1925; 232-245

Extracted Summary

The author presents eleven case summaries of patients he treated for breast cancer (*Cancer of the Breast, with a Study of 250 Cases in Private Practice, Philadelphia, 1924*). The author is an opponent of surgical treatment, X-ray and radium, since, in his opinion, the disease often recurs or metastasizes in a majority of cases so treated. He advocates a conservative approach to treatment, using dietary, hygienic and medical measures. With this kind of treatment, the author has seen the original tumor disappear, glandular involvement disappear, and, if the patients continue to live according to "exact correct lines," many live normal lives with no recurrence.

In analyzing his private case papers, the author found records of 315 patients with breast cancer that he has treated over 40 years. Upon follow-up the author found only 57 (30 deaths among post-operative cases and 27 among primary), or 18.5%, deaths among his recorded cases. The author states that for many of his cases there has been no microscopic proof, unless it was performed by other physicians, because the author does not permit biopsy, "as this would complicate the case, and expose the patient to metastases, as I have frequently witnessed in cancer in many localities." Among advanced and especially postoperative cases, whether by surgical excision, X-ray, or radium, the mortality figures are considerably higher, approximately 36%.

SELECTED CASE REPORTS

Case 1. Large, primary, ulcerating carcinoma, patient remaining well 29 years: Miss B.M.L., aged 45, was sent to me on January 4, 1894, with a well-defined carcinoma of the left breast, so diagnosed by several good medical men, one of them a surgeon of great prominence, who urged an immediate operation, which was to have been performed by him on the day following that on which she came to me, but escaped. The mass had been noticed for a month or so and had steadily enlarged and had begun to ulcerate, with slight axillary adenopathy. There was a hard mass nearly two inches in diameter in the upper outer quadrant of the breast, well defined, and not painful on moderate handling, with some skin adherence, and an ulceration in the centre of the mass.

Under full dietary, hygienic, and medical measures there was almost immediate improvement and two months later the lump was much less distinct, flatter, and much healed, and within 11 months it had entirely disappeared. Being seen repeatedly, bringing a relative for treatment and for other reasons, the breast was frequently examined for 16 years and found perfectly well, and the case was reported. Recently she sent me another breast patient, and learning her address I called, and found her at 74 years, with a normal breast, 29 years after her first visit.

Case 3. Primary cancer of the left breast, remaining well over 19 years: Miss G. M., aged 44, a hard-working public school teacher, first seen November 13, 1905, had struck the breast in a fall 16 years before, but the effect passed off, and there were no sensations for 7

or 8 years, when she began to have pain, aggravated at menstruation. During the past year a lump formed, with constant pain, also recently pain in the axilla, which kept her from school. A number of medical men had already diagnosed cancer, and a surgeon of prominence in one of the large hospitals had strongly pressed for immediate operation, as the only hope, which was refused.

At her first visit there was a hard tumor 2 or 3 inches in diameter, sharply defined and nodular on the surface, in the upper segment of the left breast, with large, hard glands in the axilla. She had long been constipated and passed only about 60% of the amount of urinary solids proper for her weight and age.

Under very active treatment it was recorded 4 weeks later that there had been hardly any sensation in the breast during the previous week, whereas for the previous months she had been kept from her work in school by severe pain in the breast and axilla. The tumor had already diminished materially in size, with only moderate hardness, and she was feeling very much better, and out of doors every day, and she was again at her duties in the school.

On April 7 it was recorded that the left breast was the same as the other and that no glands could be found in the axilla, and in my first report of the case in 1915, she had been free from disease for over 9 years. A sister, aged 60, had just then died of cancer of the stomach in a distant country town.

At the last record, over 17 years from her first visit, she still remained free from cancer, and at the time of this writing I learn that she is still perfectly well, over 19 years.

Case 5. Primary carcinoma of the right breast, well for over 16 years: Mrs. BE. C., aged 44, first seen on September 19, 1892. She then had a flat tumor in the outer lower segment of the right breast, rather sharply defined and tender on pressure, which she had had for about two months. Not satisfied with my diagnosis of cancer nor with the prolonged treatment proposed, she consulted another, a very prominent surgeon, who pronounced the tumor unquestionably cancer, and urged its instant removal. I did not know of this until she informed me of it, some time later, after the tumor had entirely disappeared under medical treatment.

Under very active measures, with frequent visits, the breast became entirely normal in six months. The case was watched for over 16 years, and at the last record she continued entirely well, with no recurrence of the breast tumor or metastasis.

Case 6. Primary carcinosis of the left breast, still well 9 years: Mrs. J.T.T., a farmer's wife, aged 38, was seen in Norfolk, Connecticut, August 11, 1914. She

had been confined with her first child 4 months previously, but had not nursed the child and had no breast trouble. Four weeks before her visit she had noticed a tumor in the upper outer segment of the left breast, increasing rapidly. She had seen an excellent surgeon in a neighboring city, who diagnosed cancer, and urged instant operation.

When first seen there was a mass the size of an egg, hard and well defined, with enlarged axillary glands. Under very active dietetic, hygienic, and medical treatment of various kinds the lump disappeared slowly, and just a year subsequently it was recorded that the breast was perfectly normal, with no trace of the tumor or axillary adenopathy. She was again confined of a healthy child in June, 1916, and the surgeon who confined her, and who had made the original diagnosis of cancer, and urged immediate surgical removal, reported the breast perfectly normal, as I found it to be. She was seen frequently and the last record shows that the breast and axilla still remain perfectly well and free from cancer, 9 years after her first visit, and even up to the present date.

Cancer of the Breast and the Menopause

SMITHERS DW

Journal of the Faculty of Radiologists (Clinical Radiology) 4: 1952; 89-96

Extracted Summary

The relationship between the period of hormone readjustment in women during middle life and cancer of the breast has long been a topic of controversy. If anything is certain about it, it is that this relationship is a complex one and its study difficult.

My impression is that the state of endocrine therapy for patients with breast cancer, whether by surgery, radiotherapy, or the administration of hormones is unsatisfactory. It seems to me that most of it is ineffectual, much of it increases the patient's discomfort of mind and body, some of it is harmful, and little of it is rational.

My object has been to indicate some of the complexities of the subject and to ask for a pause for thought before the surgeon, having removed both ovaries and both adrenals, contemplates taking the pituitary and one or two parathyroids as well, the radiotherapist, having irradiated the ovaries and the pituitary, decides where to strike next, and our amateur endocrinologists, having added nausea, vomiting, edema, bleeding, acne, enlargement of the clitoris, undesired increase in libido, deep voices, and beards to their patients with breast cancer, not always in fair exchange for the symptoms they already had, add still more symptoms to the list.

The pause for thought is so necessary because here we have a subject of fundamental interest to cancer research and treatment. If normal growth and development of the breast is under hormone control, if some degree of control of the more differentiated growths can occur naturally, and if marked tumour regression is to be seen occasionally with hormone treatment, we are clearly presented with an opportunity for gaining knowledge. If changes in metabolism effected by alterations in hormone balance can influence tumour growth or promote normal tissue resistance, we may have a chance of enhancing the effect of radiotherapy.

SELECTED CASE REPORTS

In October 1937, I saw a woman who had attended the hospital first in June, 1936, with a lump in the right breast which she had had for two years. The notes stated that at that time there was an ulcerated mass in the right breast measuring 8 centimeters in diameter. This was surrounded by subcutaneous nodules extending from the midline anteriorly nearly to the posterior axillary fold. There was a fixed mass of nodes in the right supraclavicular fossa and hard, mobile lymph nodes were easily palpable in both axillae, and in the left supraclavicular fossa as well. Her chief complaint had been pain in the back due to extensive secondary deposits in the bones. No treatment had been given.

At the time when I saw her first, sixteen months after the above notes had been made, she was well and the right breast showed some puckering and scarring but no sign of any residual tumour. All the skin nodules had disappeared, but there were small pitted scars to mark the place where each had been. No lymph nodes could be felt in either axilla or in either supraclavicular fossa. The radiograph of her spine showed no clear change in the degree of bone destruction but she had lost her pain. She seemed to be doing so well without treatment that she was advised to get out of bed, where she had been for the whole sixteen months, and she slowly returned to a more normal existence at home.

Ten months later, in August 1938, she developed a cough, lymph-nodes were again felt in her neck, her general condition deteriorated rapidly, and she died with secondary deposits in the lungs. At the time of her death there was no sign of any recurrence of the primary tumour or skin nodules. On first admission to the hospital she had been 46 years of age. She was known to have had her primary tumour for at least two years and, at the time of her admission, her periods were becoming irregular, she was losing less, and soon after her admission they stopped.

I have seen two patients recently in whom I think it probable that similar spontaneous regression occurred which has now led me to attribute the regression

in each case to the natural menopause. In July of this year an unmarried woman of 64 was sent to me by Mr. York Mason of St. Helier Hospital. She had complained of a swelling of the left arm for six months, and ten days before she came to see me a lymph node had been removed from the left axilla and had been found to be infiltrated by carcinoma. She had a scar in the left axilla and beneath this a mass of hard fixed lymph nodes 3.5 centimeters in diameter. The left breast was shrunken and deformed, the nipple was tilted, and there was a circular, scarred area 3.5 centimeters in diameter in the lower and outer quadrant, the skin being pale and depressed but with no underlying mass palpable. The patient stated that she had had the menopause at the age of 46, and that about that time, either just before or just afterwards, she cannot be certain which, her breast began to change in shape. It contracted slowly and shrank beneath the nipple, the nipple turning over, leaving the deformity which she now has, and which she says has been present for more than 17 years.

The third patient I saw only last month. She was sent to me by Mr. Harold Dodd, whom she had just consulted after being under a homeopath for fourteen years. She had a carcinoma of the right breast and multiple deposits in bone. Her story was most clearly told: She had first seen the lump in 1937, and shortly afterwards had gone to the homeopath; she had noticed little change in the lump at first, which seemed to be growing slowly, but "just before the war" it had almost completely disappeared, and though it had slowly returned it was only recently that the contraction and commencing ulceration had worried her and that she had developed pains in the back. When asked about the menopause she replied at once that her last period had been in July 1939. She was naturally reluctant to have anything done, and wished once again to consult the homeopath who had treated her so successfully for fourteen years. I offered to try to relieve her pain, but found myself in sympathy with her desire to keep her trust where it had been placed for so long.

Natural History of Untreated Breast Cancer (1805-1933)

Comparison of Untreated and Treated Cases According to Histological Grade of Malignancy

BLOOM HJG; RICHARDSON WW; HARRIES EJ
British Medical Journal 2: July 28 1962; 213-221

Extracted Summary

A series of 250 cases of untreated breast cancer from the records of the Middlesex Hospital between 1805 and 1933 are reviewed. In all cases, a post-mortem examination had been performed, and in 86 cases seen between 1902 and 1933 histological material was also available. Age distribu-

tion was comparable to that seen in a large modern treated series. Nearly three-quarters of the cases had a history longer than one year, 24% more than 3 years, and 12% more than 5 years. The vast majority of cases were advanced when first seen, 74.4% being in stage 4, 23.2% in stage 3, and only 2.4% in stage 2. There were no stage 1 cases.

No definite relationship was found between age and prognosis, although it is possible that the outlook for patients in the fifties may be slightly worse than for those in other age groups.

Patients with breast cancer may survive for many years without specific treatment. Spontaneous regression was not observed although fluctuation in growth rate of the primary tumour was noted in one patient.

The mean duration of life from onset of symptoms was 3 years: 18% survived 5 years, 3.6%, 10 years, and 0.8% 15 years. The longest survival was 18 years and 3 months. Three other patients survived over 13 years.

Regression of Pulmonary Metastases of a Breast Cancer

DAO TL

Archives of Surgery 84: 1962; 574

Extracted Summary

A case of spontaneous disappearance of pulmonary metastases of a breast cancer after radical mastectomy is reported. The subsequent reappearance of the initial pulmonary lesion and the later complete regression of that lesion along with many other pulmonary metastases in both lungs after adrenalectomy proved that the lesion was a metastasis of the breast cancer, even though there was no histological diagnosis. The highly hormone-dependent mammary cancer in this patient led me to suggest that the alteration of adrenal cortical activity following a two-stage bilateral radical mastectomy, rather than the host defense factor, was involved in the spontaneous regression of the pulmonary metastases.

SELECTED CASE REPORT

The patient was first seen at the Roswell Park Memorial Institute on October 10, 1956, at the age of 65. She was referred here for the diagnosis and treatment of a mass in the right breast and axilla, a mass that had been noticed "about 2 months" before admission.

Physical examination at that time revealed a firm nodular mass in the right breast at about 12 o'clock, with retraction of the nipple. Just posterior to the anterior axillary fold, there was a 2 centimeter mass, firm, nontender, and fixed to the skin. In the left breast at about 1 o'clock there was a 2 centimeter firm mass, also with skin retraction. No axillary mass was palpable on the left side. The clinical impression was one of bilateral carcinoma of the breast with right axillary metastasis.

Preoperative x-ray examination of the lungs revealed a large nodular density in the right lower lung field, suggestive of a metastatic lesion. Planigraphic examination in the anteroposterior direction of the right lower chest delineated the lesion at a depth of about 10 centimeters. An x-ray of the skeleton did not reveal any evidence of metastasis.

The diagnosis of this solitary pulmonary lesion being uncertain, a bilateral radical mastectomy was contemplated. A right radical mastectomy was performed first,

and after an interval of 10 days, a left radical mastectomy. Histological examination of the right breast revealed duct carcinoma with metastases to 13 of the 18 axillary lymph nodes removed, and that of the left breast a moderately well-differentiated carcinoma. The patient had an uneventful course in the hospital and was discharged about 3 weeks after the second radical mastectomy.

Because of the pulmonary lesion in the right lower lung field, the patient was closely observed and repeated chest films have been taken since the operation. About 2 months after the operation, the lesion in the right lower lung field showed a marked diminution in size. Four months after the operation, the mass completely disappeared. Repeat chest films were taken at 2 month intervals thereafter. No evidence of any recurrence of the pulmonary lesion was noticed until June 1958, at which time the previously observed nodular lesion again became visible. In January 1959, the same lesion in the right lower lung field increased in size markedly, and, in addition, nodular lesions were also seen in the right upper middle lung field. The patient, however, was entirely asymptomatic. By August 1959, bilateral pulmonary metastases were observed.

In view of the marked progression of the disease, a

bilateral adrenalectomy was performed on September 22, 1959. Three months after the adrenalectomy, the patient had a spectacular response, the pulmonary lesions in the right and left lower lung fields completely disappearing. The patient continued to show regression of the pulmon-

ary metastases until February 1961, 17 months after the adrenalectomy, when slight progression of the pulmonary metastases was again observed. Despite progression of disease, the patient is still asymptomatic, and is living and well at the time of this report.

Spontaneous Regression of Breast Cancer

LEWISON EF

National Cancer Institute Monographs 44: 1976; 23-26

Extracted Summary

The dramatic but rare regression of a verified case of breast cancer in the absence of adequate, accepted, or conventional treatment has been observed and documented by clinicians over the course of many years. In my practice limited to diseases of the breast, over the past 25 years I have observed 12 patients with a unique and unusual clinical course valid enough to be regarded as spontaneous regression of breast cancer. These 12 patients, with clinically confirmed breast cancer, had temporary arrest or partial remission of their disease in the absence of complete or adequate treatment. In most of these cases, spontaneous regression could not be equated ultimately with permanent cure. Three of these case histories are summarized, and patient characteristics of pertinent clinical interest in the remaining case histories are presented and discussed. Despite widespread doubt and skepticism, there is ample clinical evidence to confirm the fact that spontaneous regression of breast cancer is a rare phenomenon but is real and does occur.

The author presents several clinical characteristics of breast cancer, which are for the most part generally unexplained. 1) Advanced breast cancer is often a widely disseminated disease, yet it almost never metastasizes below the elbow or below the knee. 2) Metastatic breast cancer can and often does involve every organ in the body except one. This one structure is the largest in the human body and consists of the voluntary or striated muscles. There are over 400 striated muscles on each side of the body, and although they may be affected by direct invasion of cancer, they are never affected by metastatic dissemination. 3) Breast cancer is a common disease throughout the animal kingdom, frequently affecting the dog, cat, mouse, rat, and most other mammals. However, the cow with its large and highly specialized mammary gland is the only exception to this prevalent cancer. Breast cancer of epithelial origin has rarely, if ever, been found in the udder of a cow, and these domestic animals have been very carefully examined over a long period of time.

Regression of Cancer After Intensive Meditation

MEARES A

Medical Journal of Australia 2: 1976; 184

Extracted Summary

There is evidence to suggest that some cancers are influenced by immunological reactions. As there is some similarity between immunological reactions and allergic reactions, some allergic reactions can be modified by meditative experience. Furthermore, some cancers are influenced by endocrine reactions, and some endocrine reactions can be modified by meditative experience. With these ideas in mind the author wrote to the correspondence column of this journal, on October 25, seeking referral of suitable cancer patients to conduct a small private experiment to see if the progress of their condition could be influenced by intensive meditation. Only three patients made themselves available and two of them soon dropped out of the experiment. The case of the remaining patient in the study with pathologically proven carcinomas in both breasts who experienced regression of metastases following intensive meditation is reported.

SELECTED CASE REPORT

The third patient, a single woman aged 49 years, has continued steadfastly in the experiment for the past six months. She had pathologically proven carcinomas of both breasts. She had been given radical radiotherapy to both breasts, with initial regression of the tumours. However, they soon recurred and she developed radiologically proven metastases in the spine. She underwent oophorectomy. There was a remission of symptoms, but she relapsed again and had treatment with Laetril (an extract of the apricot kernel) in Mexico. Her condition deteriorated and she required a blood transfusion. Treatment with cytotoxic drugs had been strongly advised, but for reasons of her own the patient kept putting off the decision to accept the treatment.

When I first saw the patient six months ago she was frail, debilitated, and in pain. Her left breast was wooden and immovable on the chest wall and the skin over it was so tight that it appeared in danger of rupture. The right breast had large, wooden lumps in it and the nipple was retracted. Her general condition continued to deteriorate for the first six weeks in which I saw her. Her weakness became greater and she had severe pain in the back. Her condition necessitated two more transfusions. She developed ascites which had to be tapped on two occasions.

After six weeks further deterioration gradually ceased. Strength began to return. After the second paracentesis her abdomen started to refill, but the fluid has been reabsorbed. Three months ago the patient was barely able to keep down any food at all, whereas now she says she had enjoyed steak and onions. Initially she barely had the strength to come to my rooms and now she has been swimming in a friend's pool. She has had no analgesic treatment at all for the past ten weeks. The left breast is still hard, but there are definite soft patches developing in the under surface. It is now freely movable on the chest wall, and the skin is still tight, but very much less so than when the patient first presented. The nipple of the right breast is no longer retracted. Her abdomen is now soft to palpation. Her face has filled out, but there is still very marked loss of flesh above and below the clavicles. In spite of the loss of fluid from her abdomen, in the last seven weeks she had gained 9 pounds in weight.

In the six months the patient has attended more than 100 sessions of intensive meditation in a small group under my guidance. She has also practised what I have shown her for many hours, both in my rooms and at her home.

Atavistic Regression as a Factor in the Remission of Cancer

MEARES A

Medical Journal of Australia 2(4): July 23 1977; 132-133

Extracted Summary

It is suggested that the atavistic regression of the mind in intensive meditation is accompanied by a similar physiological regression, and that this may involve the immune system and so influence the patient's defences against cancer. This article continues the case report of a patient with carcinoma of the breast in which regression of metastases occurred after intensive meditation.

SELECTED CASE REPORT

Last year I reported a case of regression of advanced cancer after intensive meditation. (*Medical Journal of Australia* 2 (1976) 184)...The significant episode in the patient's recovery is that after the publication of the report, she had a serious relapse. I went overseas for 3 1/2 weeks and the patient was left to continue her meditation unaided. She soon relapsed. Her breast became hard again and the skin over it became tense and discoloured. Her physical condition had clearly deteriorated. On my return, I inquired in some detail about the way she had been meditating. It gradually became clear that she had changed the pattern of her meditation. With her initial success she had become very confident. Her recovery was hailed as a kind of miracle. Her photograph was in the papers. She gave television and radio interviews and was invited to give talks

on how she "beat" cancer. In this burst of confidence, she departed from the extreme simplicity of the meditation she had been taught. She improved upon it. She would tell her cancer to get better. She would will it to get better. "I will make you get better." And of her own initiative she came upon the way of visualizing her cancer getting better. In this form of meditation there was clearly little atavistic regression. However, when she returned to the extreme simplicity of the meditation in which she was originally instructed, her breast softened again, she put on weight, and strength returned. She had continued well for the nine months since this episode. From this it would seem that the atavistic regression, the going back to a simple and more primitive pattern of functioning was an essential factor in the patient's recovery.

Regression of Cancer After Intensive Meditation Followed by Death

MEARES A

Medical Journal of Australia 2: 1977; 374-375

Extracted Summary

The author reports the follow-up of a case reported in two previous articles (Med J Aust, 1976, 1977) in which a patient with carcinoma of the breast experienced regression of metastases following intensive meditation.

SELECTED CASE REPORT

In a recent article (Med J Aust, 1977) I referred to a patient with advanced cancer who made a dramatic remission following intensive meditation, who relapsed, and who made a second remission when her faulty style of meditation was corrected. At the time of submission of the article, the patient was well, strong, active and free of pain. Owing to the considerable professional interest in the subject, I now wish to report that the patient has since died. She developed ascites, was admitted to hospital for paracentesis, elected to have chemotherapy, and died within a few days.

In a strange, indirect, and negative fashion, her death tends to give further support to the idea that cancer growth can be influenced by intensive meditation. A few weeks ago, in Melbourne, considerable publicity was given to the treatment of advanced cancer by Dr. Brych in the Cook

Islands. Without my knowledge, the patient concerned and a small coterie of cancer patients who were attending me for meditation, became emotionally involved in the matter, and two of them left to seek treatment in the Cook Islands. It was at this time that the patient relapsed. She told my secretary that, if she had the money, she, too, would seek further treatment in the Cook Islands. My interpretation of these events is that this situation caused doubts in her mind, and caused her to lose her ability for effective meditation and the still-dormant cancer became active. Her ready acceptance of the chemotherapy, when 18 months previously, in similar circumstances, she had steadfastly rejected offers of such help, seems to have been an outward expression of her new-found doubts about the meditation which had helped her so much in the past.

Spontaneous Regression of Breast Carcinoma

KRUTCHIK AN; BUZDAR AU; BLUMENSCHNEIN GR; LUKEMAN JM

Archives of Internal Medicine 138(11): Nov 1978; 1734-1735

Extracted Summary

Spontaneous regression of breast carcinoma occurred in a patient with a malignant pleural effusion and bone metastases. The patient did not receive any form of hormonal manipulation or systemic chemotherapy. It is postulated that the spontaneous regression of the carcinoma may have been caused by immunological factors.

SELECTED CASE REPORT

A 60-year-old woman developed retraction of the areola of the left breast in November 1972. She did not seek medical attention until January 1973, when a mass was found in the left breast with retraction of the areola. The patient was referred to M. D. Anderson Hospital and Tumor Institute. The patient had had an abdominal hysterectomy without oophorectomy 15 years before the development of the breast mass. Physical examination showed a 6.5 x 6.5 centimeter central breast mass with skin fixation, peau d'orange, and nipple retraction. Additionally, in the left axilla there were two 1.5 x 1.5 centimeter palpable axillary nodes. In the left supraclavicular area, a 1 x 1 centimeter node was palpable. A needle biopsy of the left breast showed carcinoma of the breast.

The patient's breast carcinoma was inoperable. Additional diagnostic workup consisting of chest x-ray film, bone scan, and hematological profile (complete blood cell count, hemoglobin measurement, WBC count, and platelet count), and blood chemistry studies, which included determinations of SGOT, alkaline phosphatase, calcium, and total bilirubin, were within normal limits. The absolute lymphocyte count was 2,121/mm³. The patient received radiation therapy in a dose of 5,000 rads in five weeks to the left breast and regional lymph nodes. At the end of radiation therapy, the left supraclavicular nodes were no longer palpable and the axillary nodes on the left regressed in size and measured 1 x 1 centimeter. There was no definite mass palpable in the breast.

The patient returned for follow-up examination in September 1973, and results of physical examination were within normal limits. A chest x-ray film indicated a left pleural effusion. Thoracentesis was performed and 150 milliliters of pleural fluid was removed; it contained malignant cells consistent with primary breast carcinoma. A skeletal survey showed a lytic metastases in the eighth and ninth right ribs. The absolute lymphocyte count was $2,002/\text{mm}^3$. The patient did not receive any further therapy. The patient was seen again in January 1974, and there was no evidence of a pleural effusion on chest x-ray film. The absolute lymphocyte count was $1,350/\text{mm}^3$. The patient was observed periodically in our clinic and remained free of disease. Recently, additional cytological specimens were prepared from cell blocks stored from the

original pleural effusion in 1973. The specimens were reviewed and compared to slides of the patient's primary tumor; they were identical. A recent chest x-ray film, performed in December 1977, was normal, and the lytic metastases of the ribs showed definite evidence of healing.

On a follow-up clinic visit in May 1978, the patient remained free of metastatic disease. We had planned to perform further testing that was to consist of a standard battery of skin tests, resting pituitary and adrenal activity and the response to stimulation and suppression, and a study of the serum for factors cytotoxic for human breast carcinoma cells. However, the patient did not agree to have any further tests done. The absolute lymphocyte count at this time was $3,298/\text{mm}^3$. The patient was euthyroid with no clinical signs of hypoadrenalism.

Regression of Recurrence of Carcinoma of the Breast at Mastectomy Site Associated with Intensive Meditation

MEARES A

Australian Family Physician 10: Mar 1981; 218-219

Extracted Summary

A case is reported of a patient with recurrence of breast carcinoma who practiced intensive meditation each weekday for a month in the author's presence. Within that time the ulcer on the mastectomy scar was almost completely healed.

SELECTED CASE REPORT

The patient is a 54-year-old married woman with two adult children, the proprietress of a fashion shop. Fourteen months prior to seeing me she developed a mass around her left nipple. She had a radical mastectomy, with the pathologist reporting a cellular scirrhous carcinoma with involvement of the axillary nodes. Post-operatively she had telecobalt therapy. Four months later skin nodules appeared. These were treated with radiation without effect on the nodules. Tamoxifen was tried without effect and the patient was advised to have chemotherapy. She refused this advice, as she had nursed her sister with cancer three years before she herself developed the disease. She stated she would never have chemotherapy after seeing what it did to her sister.

The patient then went to Germany where she says she was given injections, and has since continued the regime with weekly injections of Masterid (an anabolic steroid) and 42 tablets a day which she imports from Germany,

and which she has been told contain an enzyme from pineapple. For several months she has been receiving help through relaxation from her family doctor.

She stated that two weeks prior to seeing me she had read one of my books and started to practise the mental exercises described in it; she stated that she thought the edges of the large ulcer had already started to heal.

The patient attended each weekday for a month for intensive meditation. By this time there was clear evidence of healing. It was arranged that the patient should return to her home in another State, and come back for further treatment in a month's time. However, by then the ulcer had nearly healed, the patient said she was well and felt it was unnecessary to return for further treatment. The ulcer completely healed, and the hard raised nodules have disappeared. She has, however, recently developed a bony metastasis for which she has had cobalt radiation.

Spontaneous Regression of Breast Carcinoma

Follow-Up Report and Literature Review

ROSS MB; BUZDAR AU; HORTOBAGYI GN; LUKEMAN JM

Journal of Surgical Oncology 19(1): Jan 1982; 22-24

Extracted Summary

A case of spontaneous complete regression of metastatic breast carcinoma (malignant pleural effusion and bone metastases) was previously reported from M. D. Anderson Hospital and Tumor Institute. The patient did not receive any form of hormonal manipulation or systemic chemotherapy. This patient has now relapsed after 72 months of spontaneous complete remission, and a follow-up of her clinical history is presented. A search of the literature for previously reported instances of spontaneous regression of breast carcinoma indicates that this event is exceedingly rare.

SELECTED CASE REPORT

A detailed clinical history prior to the time of relapse was published in the original report of this case. (Krutchik AN et al., *Archives of Internal Medicine* 138 (1978) 1734-35). In summary, a 60-year-old woman presented to M. D. Anderson Hospital and Tumor Institute in January 1973, with a 3 month history of a left breast mass and nipple retraction. A 6.5 x 6.5 centimeter central breast mass was present with skin fixation, peau d'orange, and palpable ipsilateral axillary and supraclavicular adenopathy. A needle biopsy of the mass showed carcinoma of the breast. Other than the supraclavicular adenopathy, no distant disease was demonstrated by chest radiographs, bone scan, or serum chemistry survey that included alkaline phosphatase, calcium, transaminases, and bilirubin. The lesion was considered inoperable, and primary therapy consisted of irradiation to a dose of 5,000 rad over 5 weeks to the breast and regional lymph nodes. No clinically evident residual disease remained at the completion of radiation therapy.

In September 1973, follow-up examination disclosed a left pleural effusion. Diagnostic thoracentesis produced 150 milliliters of fluid containing malignant cells consistent with adenocarcinoma of the breast. A radiographic skeletal survey showed lytic metastases in the right eighth and ninth ribs.

The patient failed to return to our clinic for follow-up and initiation of systemic therapy. No therapy was sought

or received from other physicians or cancer treatment centers. When at the urging of her family she did return in January 1974, she was asymptomatic and the chest radiographs were without evidence of pleural effusion. Subsequently additional cytologic slides were prepared from cell blocks stored from the original effusion specimen. These were reviewed and compared to slides of the patient's primary tumor and were considered identical.

The patient was subsequently evaluated periodically at our institution and remained free of disease until February 1980, when a left pleural effusion was again documented. Thoracentesis produced fluid with a protein of 3.8 mg/100 ml, a glucose of 108 mg/100 ml, and a carcinoembryonic antigen (CEA) of 95.2 nanograms/ml. In retrospect, it was noted that the peripheral blood CEA had been rising gradually from normal levels (4.1 nanograms/ml in May 1978) to 46.9 nanograms/ml in February 1980. Cytologic examination of the pleural fluid again revealed malignant cells similar to those obtained in 1973, as well as clumps of such cells ("Zellenballen").

In April 1980, treatment was initiated with an investigational antiestrogenic agent that produced no objective improvement. In June 1980, therapy was changed to tamoxifen. The patient has since manifested a decrease in pleural effusion. The peripheral blood CEA has declined progressively (33.4; 19.4; 13.0) to a level of 13.4 nanograms/ml in December 1980.

Breast Cancer, Immunological Factors Affecting Incidence, Prognosis and Survival

Part I: Factors Affecting Host Resistance and Response to Treatment.

Part II: The Immunopotentiating Effects of Concurrent Infections, Inflammation or Fever

Part III. Immunotherapy, Effects of Bacterial Vaccines

NAUTS HC

Cancer Research Institute Monograph 18: 1984; 261pgs

Extracted Summary

In Part I of this study the author analyzes immunological factors affecting incidence, prognosis and survival in breast cancer and presents pertinent data relating to host resistance of breast cancer. Part II includes all known cases in which complete or partial regression occurred "spontaneously" following concurrent infections, inflammation or fever. In Part III are found all cases with microscopic confirmation of diagnosis known to have received immunotherapy, the mixed bacterial vaccines of *Streptococcus pyogenes* and *Serratia marcescens*, formerly known as the Coley Toxins, now called Mixed Bacterial Vaccines (MBV).

SELECTED CASE REPORT

Case 15: Inoperable rapidly growing spindle cell sarcoma of the pectoral region and breast, confirmed by microscopic examination of material removed at biopsy by Drs. B. H. Buxton, E. K. Dunham of New York, and William H. Welch of Johns Hopkins Hospital, Baltimore. (Original reference: W. B. Coley, *American Journal of Medical Science* 131 (1906) 373-430)

Previous History: Miss E.E.F., female, aged 42, of New Britain, Connecticut. The patient's paternal grandmother had died of carcinoma of the breast, but the family history was negative for tuberculosis or specific disease. The patient's previous health had been good. Onset, in October 1895, she first noticed a hard lump below the left clavicle in the pectoral and axillary region. This grew rapidly and in two months had reached the size of an orange. It was firmly adherent to the deep vessels and extended well into the axilla. Her general health deteriorated and she lost 24 pounds in weight. She consulted Dr. M. Storrs of Hartford, early in December 1895. A consultation was held with McKnight, attending surgeon at the Hartford Hospital, and both surgeons regarded the condition as entirely inoperable. The patient was rapidly losing strength and weight. It was decided to try toxin therapy under Dr. W. B. Coley's direction.

Toxin Therapy (Buxton VI): Injections were begun by Storrs and Dr. R. H. Griswold on December 16, 1895, the day following the patient's admission to the Hartford Hospital. The initial dose was one drop, which was gradually increased to a maximum of 8 minims. The first chill occurred after the fourth injection, on December 29. Injections were given every two days until February 8, during which time 39 were administered, 18 of which produced distinct chills. The dose was 8 minims on February 8. The following day a more potent solution prepared from more

virulent cultures was obtained, and the dose was reduced from 8 minims to one minim. In spite of reducing the dose of this injection, it produced the most violent chill. This more potent preparation was continued and caused chills in doses of 1 to 3 minims during the next five weeks, injections being given daily in this period. The patient reported: "Chills came on 30 to 90 minutes after treatment, lasting 30 to 45 minutes. When the new stronger toxins were used (February 9) I had the worse chill of all; with that toxin the chill would come on sometimes half an hour after the treatment. The days I had a chill I had less pain and felt better after the chill than the days when I had none..." (This patient did not take her temperature regularly, it was usually about 100°F., so that the maximum febrile reactions in this case are not known.) The patient remained in the hospital only a short time; thereafter the injections were made at home or in the doctor's office.

The tumor began to shrink shortly after the injections were begun. It was incised nine times during the course of the treatment, in order to facilitate the drainage of necrotic tumor tissue. The discharge increased after the more potent toxin was used. All the incisions were thoroughly irrigated, every time an injection was made, for nearly three months. (This was a painful process, and it is doubtful whether such a procedure should be employed in treating future cases.) During the treatment the patient's appetite was not very good, but she ate in order to maintain a little strength. A total of 76 injections was given in three months.

Clinical Course: By the latter part of March 1896, a little over three months after the toxins were begun, the growth had entirely disappeared and the patient had gained rapidly in weight and strength, so that she soon regained the 25 pounds she had lost prior to toxin therapy.

Coley presented her before the New York Surgical Society on November 11, 1896, and also before the Clinical Congress of Surgeons of North America in November, 1912. She remained in good health, married, and when last traced by Coley shortly before his own death she was well except for pain in her knee joints. On October 10, 1939 (at the age of 86) she was seen by Dr. Philip G.

McLellan of Hartford, who stated that examination of the pectoral region showed nothing but the scarring of the biopsy and the sinuses. Shortly thereafter she developed a small basal cell epithelioma at the left side of her nose. She died on May 2, 1943, at the age of 89, of bronchopneumonia and decompensated arteriosclerotic heart disease. This was 48 years after onset.

An 1846 Report of Tumor Remission Associated with Hypnosis

GRAVITZ MA

American Journal of Clinical Hypnosis 28(1): July 1985; 16-19

Extracted Summary

It is now recognized that psychological factors may play a significant role in the etiology and progress of neoplastic disease, and in recent years hypnosis has been utilized as a therapeutic agent against the illness. This paper discusses an 1846 report of what may be the first association of hypnosis with the remission of a medically diagnosed breast tumor in a young female patient. Several possible explanations for this development are considered, including misdiagnosis, spontaneous remission, and mechanisms within the body's immune system.

SELECTED CASE REPORT

The clinical case in point occurred in 1846, while he [La Roy Sunderland; 1804-1885] was presenting a series of lectures in Boston shortly before the introduction of ether anesthesia. Sunderland was asked to render insensitive to surgical pain a young woman who was to have excised "a cancer (a tumour bigger than a hen's egg)" from her breast (Harte, *Hypnotism and the Doctors*, [London: Fowler Vol. II, 1903, p.211-212]). The exact nature and diagnosis of this large growth is unclear from the published account, as the term tumor generally refers to a mass which can be either inflammatory, cystic, traumatic, benign, or malignant: The last is the condition most properly described as cancer. By 1846 the use of hypnotic anesthesia in surgery had already been described for several decades, and a painless mastectomy had been undertaken in 1829 in France.

Sunderland stipulated that the subject had to attend his lectures nightly, so that she could come fully under the influence of his treatment. This preparatory process resulted in the development of self-induction, as intended. Although no information was provided as to the actual time interval which elapsed between preparation and the scheduled surgery, the account indicated that it was only several days. Sunderland accompanied the patient to the operating room, and he subsequently reported the following: "At the appointed moment I had Mrs. Nichols spell-bound in the position directed by the surgeon. Her whole muscular system was in a state of cold rigidity resembling the sleep of death. Four surgeons were waiting below, and now, upon notice which I gave them that all was ready, they came up into the room where the patient was

entranced. They instantly spread their surgical instruments upon the table, which was supplied with water, sponges, and all the implements necessary on such occasions. The first thing Dr. Walker did was to search for the location of the cancer. After manipulation for some minutes, he turned to the surgeon who stood nearest to him, and said, 'The bounds of the tumour do not seem to be well defined.' He then left, and the second surgeon tried to find the tumour; but in a few moments he gave it up, and was succeeded by the third and the fourth. Then Dr. Walker examined the patient once more, and began to look somewhat embarrassed. Each one of the surgeons now examined the patient over again, and twenty minutes more they spent in searching for the tumour, for which one of them had been treating that same lady for a year and a half. The surgeons now left the patient, and putting their heads together in a corner of the room, they whispered something I could not hear; when Dr. Walker said to me, "We have concluded it best not to operate" I asked, "Why not?" and he replied, "We do not find that there is any tumour there." With this statement, the sticking plaster, the scalpel, and other instruments disappeared, and now my attention was given to the restoration of the patient...

During the few days she had been Pathetised, the tumour and the pain had disappeared as if by magic, and as they have now been gone for fourteen years the presumption is that she may be considered cured. "...I give this as a remarkable case of self-induction, and the self-healing energies of the human organism..."

SUPPLEMENTAL REFERENCES
NEOPLASMS OF THE FEMALE BREAST

- Fall von Gleichzeitig über eine Sehr Grosse Hautpartie Ausgebreitetem Erysipel
MOSENIGEL K
Archiv für Klinische Chirurgie 12: 1871; 107-111
- Brustkrebs durch das Emmerich-Scholl'sche Erysipelserum Geheilt
SCHULER T
Deutsche Medizinische Wochenschrift 21: 1895; 611-612
- An Analysis of 46 Cases of Cancer of the Breast Which have been Operated Upon and Survived the Operation 5 to 32 Years
BRYANT T
British Medical Journal 1: May 17 1902; 1200-1203
- Medical Aspects of Carcinoma of the Breast
OSLER W
British Medical Journal 1: Jan 6 1906; 2349-2352
- Spontaneous Regression of Cancer
SCOTT JB
British Medical Journal 1: Feb 1935; 230
- Metastatic Carcinoma After Forty Years
DAVIDSON WR; RATCLIFFE AW
Indiana State Medical Association. Journal 39: Apr 1946; 165-166
- Spontaneous Regression of Pleural Carcinosis in Breast Cancer: Report of a Case
NOHRMAN BA
Acta Radiologica 33: 1950; 12-15
- On a Case of Spontaneous Regression of Cutaneous Metastases of a Malignant Breast Tumor (ITA)
LAZZARI A; BIANCHI CM
Bollettino Societa Medica Chirurgica Cremona 19: Jan-Dec 1965; 33-46
- Malignant Pericardial Effusion Secondary to Metastatic Breast Carcinoma. A Case of Long-Term Remission
HIRSCH DM JR; NYDICK IN; FARROW JH
Cancer 19(9): Sep 1966; 1269-1272
- Long-Term Remission Following Castration for Advanced Breast Cancer
LIECHTY RD; PALUSKA GM
Journal of the Iowa Medical Society 61(4): Apr 1971; 216-218
- Spontaneous Remission of Proven Cancer
EIDEMILLER LR; FLETCHER WS; DENNIS DL; KRIPPAEHNE WW
Northwest Medicine 70(8): Aug 1971; 539-543
- Long-Term Follow Up of Breast Cancer Patients: The 30-Year Report
ADAIR F; BERG J; JOUBERT L; ROBBINS GF
Cancer 33(4): April 1974; 1145-1150
- Polyneuropathy with Vagus and Phrenic Nerve Involvement in Breast Cancer: Report of a Case with Spontaneous Remission
HANDFORTH A; NAG S; ROBERTSON DM
Archives of Neurology 41(6): Jun 1984; 666-668