

# Acemannan, a Polysaccharide Extracted from *Aloe vera*, Is Effective in the Treatment of Oral Aphthous Ulceration

Kanokporn Bhalang, PhD, Pasutha Thunyakitpisal, PhD, and Nuttanit Rungsiriratean, DDS

## Abstract

**Objectives:** The objective of this study was to elucidate the safety and effectiveness of acemannan, a polysaccharide extracted from *Aloe vera*, in the treatment of oral aphthous ulceration.

**Design:** A skin patch test was performed on 100 healthy subjects, and 0.5% acemannan in Carbopol® 934P NF (Lubrizol Corporation, USA) was applied to the oral mucosa of the lower lip of 50 healthy participants 3 times/day for 7 days. Oral examinations and blood tests measuring liver and kidney function were performed prior to, and following, 7 days of application to assess the side-effects of acemannan when used on oral mucosa. Another 180 subjects with recurrent aphthous ulceration randomly received one of three treatments: 0.1% triamcinolone acetonide (HOE Pharmaceuticals, Malaysia), 0.5% acemannan in Carbopol® 934P NF, or pure Carbopol® 934P NF. Medications were applied to the ulcers 3 times/day for 7 days. Measurements of ulcer size and patient satisfaction ratings were performed on days 2, 5, and 7. Pain ratings were recorded daily.

**Results:** No subjects exhibited allergic reactions or side-effects to acemannan. There were no significant differences between the blood test values before and after 7 days of acemannan application. The effectiveness of acemannan in reducing ulcer size and pain was superior to that of control, but inferior to that of 0.1% triamcinolone acetonide. Patients were mostly satisfied with 0.1% triamcinolone acetonide and acemannan treatment.

**Conclusions:** Acemannan can be used for the treatment of oral aphthous ulceration in patients who wish to avoid the use of steroid medication, although the effectiveness was not comparable to that of 0.1% triamcinolone acetonide.

## Introduction

RECURRENT APHTHOUS ULCERATION (RAU) commonly occurs in the oral cavity, causing discomfort and pain.<sup>1,2</sup> RAU has a reported incidence rate of 46.7%, with ulcers seen in females more frequently than in males.<sup>3</sup> The etiology of RAU has not been identified; however, associations have been reported between RAU and immunological disorders.<sup>4</sup> Other predisposing factors include hormonal imbalance, bacterial infection, and sensitivity to certain diets.<sup>5</sup> Clinically, RAU presents as a small round, or oval, well-defined ulcer with a yellowish gray center consisting of necrotic tissue. The ulcer commonly has an erythematous border.<sup>4,5</sup> RAU has been classified into three subtypes based on the size and number of ulcerations: minor aphthous ulcers, major aphthous ulcers, and herpetiform ulcers.<sup>6</sup> Minor RAU (MiRAU) is the most common type, affecting about 80% of RAU patients. MiRAU typically presents as one to five ulcers per episode, with each ulcer varying in size from 3 to 10 mm, and resolves in 4–14 days without scarring.<sup>7,8</sup>

Currently, there is no curative management of RAU available. The aims of treatment are the reduction of pain and inflammation, as well as promoting healing, but do not include preventing the recurrence of the ulcers. Thus, the treatment of choice for these lesions is topical steroid application.<sup>9</sup> Antimicrobial agents, topical analgesics, immunosuppressive agents, anti-inflammatory agents, and laser therapy have all been used to treat RAU.<sup>4</sup> Because of the possible adverse effects from steroid treatment and the potential for the development of secondary oral candidiasis from long-term steroid use, herbal medicines have been advocated as an alternate form of treatment.

Several natural products have been investigated for the promotion of wound healing. *Aloe vera* (*Aloe barbadensis* Miller) has long been used to treat various skin conditions such as cuts, burns, and eczema.<sup>10–13</sup> *Aloe vera* has been proven to stimulate dermal wound healing in rats by increasing collagen and glycosaminoglycan synthesis.<sup>14</sup> *Aloe vera's* beneficial properties may be attributed to mucopolysaccharides present in the inner gel of the leaf, especially

acemannan ( $\beta$ -(1,4)-acetylated polymannose).<sup>15</sup> Acemannan has been reported to increase epithelial and fibroblast proliferation through the activation of growth factors.<sup>14</sup> Animal experiments also confirmed the effect of acemannan in accelerating oral wound healing and the immunomodulatory activity of *Aloe vera* gel.<sup>16,17</sup>

The safety of acemannan has been shown in an animal study of rats fed with acemannan for 14 days.<sup>18</sup> Increasing levels of proliferating cell nuclear antigen, keratinocyte growth factor-1, vascular endothelial growth factor, and type I collagen have been reported when acemannan was used on rat oral wounds.<sup>16,19</sup>

The aims of the present study were to investigate the potential for allergic reaction to acemannan when used on human skin, to assess local and systemic side-effects of acemannan when used on normal oral mucosa, and to measure the effectiveness of acemannan in the treatment of oral aphthous ulceration.

## Materials and Methods

*Aloe vera* (*Aloe barbadensis* Miller) was obtained from a local herbal supplier in Bangkok, Thailand, and the specimen (No. 051101) was deposited in the Museum of Natural Medicines, Faculty of Pharmaceutical Sciences, Chulalongkorn University (Bangkok, Thailand).

Acemannan was extracted from fresh *Aloe vera* pulp gel by homogenization, centrifugation, and alcohol precipitation as previously described.<sup>20</sup> To remove small proteins and monosaccharides, acemannan was placed into a 10,000 molecular weight cut off semipermeable dialysis bag for 24 hours and then lyophilized. The molecular weight of acemannan was analyzed by high-performance liquid chromatography (Shimadzu, Kyoto, Japan). The isolation was performed by using a column (Shodex Sugar KS-804; Showa Denko K.K., Yokohama, Japan) and compared with a P-82 standard (Showa Denko K.K., Yokohama, Japan). The monosaccharide composition and structure of the polysaccharide was determined by gas chromatography-mass spectroscopy, and <sup>13</sup>C nuclear magnetic resonance spectroscopy as previously described.<sup>21,22</sup> These analyses were consistent with prior results, confirming the polysaccharide extracted from fresh *Aloe vera* gel was acemannan.<sup>21,22</sup> The yield of the acemannan extraction was about 0.2%.

Acemannan in Carbopol® 934P NF was prepared by diluting acemannan in distilled water and then it was autoclaved and mixed with Carbopol® 934P NF. The pH was adjusted to be in the range of 6.5–7.

The present study was conducted with informed consent following protocols approved by the Chulalongkorn University Faculty of Dentistry's Committee on Investigations Involving Human Subjects. The study population comprised 150 healthy volunteers and 180 subjects with recurrent aphthous ulceration. Acemannan used in the study was extracted from *Aloe vera* and passed cellular and animal safety screening.

To investigate whether acemannan caused an allergic reaction when used on human skin, 100 healthy volunteers (50 females and 50 males) were recruited to participate in the study. One-half percent acemannan in Carbopol® 934P NF (Lubrizon Corporation, Cleveland, OH, USA) was loaded in two Finn chambers (Epitest, Tuusula, Finland) and pure Carbopol® 934P NF was loaded in two other chambers. The

chambers were then applied to the subjects' upper backs. After 48 hours, the chambers were removed and 15 minutes later, any reaction was scored according to the International Contact Dermatitis Research Group standard. Scoring was conducted again 24 hours later. The subjects and examiner were blinded as to which chambers contained acemannan.

To assess the local and systemic side-effects of acemannan when used on normal oral mucosa, 50 healthy volunteers (25 females and 25 males) were recruited to participate in the study. Subjects were instructed to apply 0.5% acemannan in Carbopol® 934P NF with a diameter of 1 cm 3 times per day for 7 days on their lower labial mucosa. Oral examination and blood tests were performed before and after 7 days of drug administration. The blood parameters assayed were serum glutamic oxaloacetic transaminase, serum glutamic pyruvic transaminase, alkaline phosphatase, T protein, T bilirubin, albumin, blood urea nitrogen, and creatinine.

To measure the effectiveness of acemannan in the treatment of oral aphthous ulceration, 180 subjects with recurrent aphthous ulceration randomly received one of three treatments: 0.1% triamcinolone acetonide (HOE Pharmaceuticals, Malaysia), 0.5% acemannan in Carbopol® 934P NF, or pure Carbopol® 934P NF. The medications were applied to the ulcers 3 times per day for 7 days. Measurement of the ulcer size was performed before treatment and on days 2, 5, and 7. Ulcer diameters were measured using a calibrated dental probe with millimeter markings, and the sizes of the ulcers were calculated using formulas for the surface area of a circle or ellipse. The ulcers were photographed alongside a visual reference of known size, and the images were analyzed using computer software (Image-Pro Plus version 4.5 for Windows, Media Cybernetics, Rockville, MD, USA).

All ulcers were diagnosed by an oral medicine specialist. Traumatic, infectious, and immunologic-related ulcers were

TABLE 1. SELECTION CRITERIA

Inclusion criteria	
1.	Male and female individuals 18–65 years of age.
2.	Willing to participate and signed the informed-consent forms.
3.	History of recurrent aphthous ulcers (at least 2 times per year) on nonkeratinized oral mucosa.
4.	Presented with 1–3 aphthous ulcers (of <48 hours duration) that were 2–10 mm in diameter.
5.	Ulcers were required to be in locations easily accessible for evaluation and treatment.
Exclusion criteria	
1.	History of allergies to acemannan, triamcinolone, or Carbopol®.
2.	Pregnancy and/or lactation.
3.	Concurrent oral bacteria/fungal/viral infections.
4.	Ulcers as a manifestation of a systemic disease process such as ulcerative colitis, Crohn's disease, Behçet's syndrome, or anemia or ulcers from trauma.
5.	Treatment with systemic steroids, oral retinoids, or other immunomodulatory agents within 1 week, or nonsteroidal anti-inflammatory drugs, acetaminophen, or any other oral topical medications within 48 hours or during project participation.
6.	Dental surgery within 2 weeks of entering the study.
7.	Orthodontic braces or retainers that might come in contact with the ulcer.

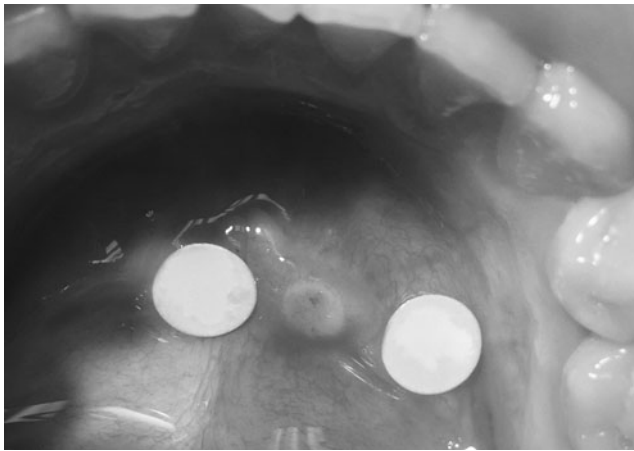


FIG. 1. An aphthous ulcer with two size references.

excluded (Table 1). If there was more than one ulcer, the ulcer with the easiest access was selected for investigation. Subjects and investigator were both blinded to the treatment type. When a subject developed RAU more than one time (at least 1 month apart), they reentered the study, receiving a different medication.

Pain ratings using a visual analog scale consisting of a 100-mm horizontal line between the endings marked “no pain” and “unbearable pain” were recorded daily. On the last day, subjects were asked to rate their satisfaction with the medication used on a scale of 0 to 10. Each subject was interviewed at each visit by the investigator regarding the emergence of any adverse reactions.

### Statistical Methods

Background and demographic data were summarized with descriptive statistics. One-way analysis of variance was performed to compare group differences in the satisfaction rating, ulcer size, and pain level at each monitoring point. All data were analyzed using SPSS software (SPSS 12.0 for Windows; SPSS, Chicago, IL). A  $p$ -value of  $\leq 0.05$  was considered to be statistically significant. Outliers were excluded from the database.

### Results

A representative lesion in this study is seen in Figure 1.

### Skin patch test

Assaying the reaction to acemannan when used on human skin revealed that no subjects had any positive allergic reaction. One subject (number 7) had mild irritation (discrete patchy erythema, no infiltration) on all treated areas (Fig. 2) 24 hours after the removal of the Finn chambers. This subject had a history of metal allergy and possibly had an allergic reaction to the aluminum component of the Finn chamber. When 0.5% acemannan in Carbopol was applied directly onto the subject, no reaction was observed.

### Blood tests

The results of assessing the local and systemic side-effects of acemannan when used on normal oral mucosa revealed that there were no significant differences in any blood parameter examined ( $p > 0.05$ ) when compared between before and after the 7-day application of the medication.

### Subject satisfaction with the treatment of oral aphthous ulceration

The three groups of subjects—0.1% triamcinolone acetone, 0.5% acemannan in Carbopol® 934P NF, and pure Carbopol® 934P NF—were well matched as to age, sex, and size and pain level of ulcerations at the first visit.

Assessment of the effectiveness of acemannan in the treatment of oral aphthous ulceration showed that subjects who received 0.1% triamcinolone acetone were mostly satisfied with the medication with an average satisfaction score of 8.3, followed by acemannan with an average score of 7.5, and control with an average score of 6.5. Analysis by analysis of variance revealed that the differences were significant ( $p \leq 0.05$ ), and the Bonferroni test confirmed that subjects were significantly more satisfied with 0.1% triamcinolone acetone and acemannan than control. The difference in satisfaction scores between subjects receiving acemannan and 0.1% triamcinolone acetone did not reach statistical significance.

Seventeen (17) subjects were treated with all three medications. When these subjects were asked to pick which medication they preferred for treatment, 76% of the subjects selected acemannan as their treatment of choice. Eighteen percent (18%) of the subjects who received all three medications chose triamcinolone, while 6% picked the control medication.




FIG. 2. Skin reaction assay results, Subject 7.

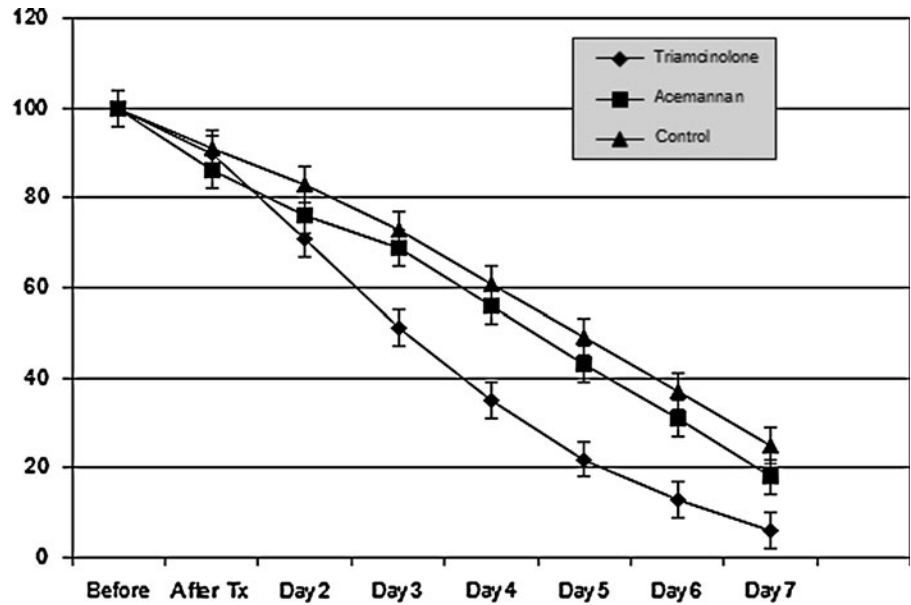


FIG. 3. Daily pain ratings (adjusted to percentage).

*Daily pain rating for the treatment of oral aphthous ulceration*

When daily pain ratings were compared between the three groups, it was found that 0.1% triamcinolone acetonide markedly reduced the pain level from day 2 onward when compared to acemannan and control (Fig. 3). Acemannan had an immediate effect in relieving pain symptoms, but its long-term effect was not comparable to that of 0.1% triamcinolone acetonide. There was a significant difference in pain reduction by 0.1% triamcinolone acetonide compared to the other groups. Subjects receiving acemannan reported lower levels of pain during the entire 7 days when compared to control, although the difference did not reach statistical significance.

*Ulcer size reduction in the treatment of aphthous ulceration*

Analysis of wound reduction among the three medications applied revealed that ulcer size was more than 30% smaller in the 0.1% triamcinolone acetonide group on day 5

compared to the control group (Fig. 4). This reduction in size was greater in the 0.1% triamcinolone acetonide group on day 7. At day 2, acemannan treatment reduced ulcer size to the same degree as 0.1% triamcinolone acetonide. At days 5 and 7, acemannan reduced the ulcer size less than 0.1% triamcinolone acetonide, but the difference was not significant. However, the reduction of ulcer size by acemannan was significantly different from that of control ( $p \leq 0.05$ ). Statistical analysis of ulcer size reduction in each group of subjects revealed that 0.1% triamcinolone acetonide and acemannan significantly reduced the ulcer size when compared to baseline while no significant reduction of ulcer size was found in the control group.

**Discussion**

In the present study, we evaluated the use of acemannan, extracted from the gel of *Aloe vera*, as a topical treatment of aphthous ulceration. As no subjects experienced any adverse reactions to the use of acemannan either extraorally or intraorally, we concluded that acemannan is safe to be used on

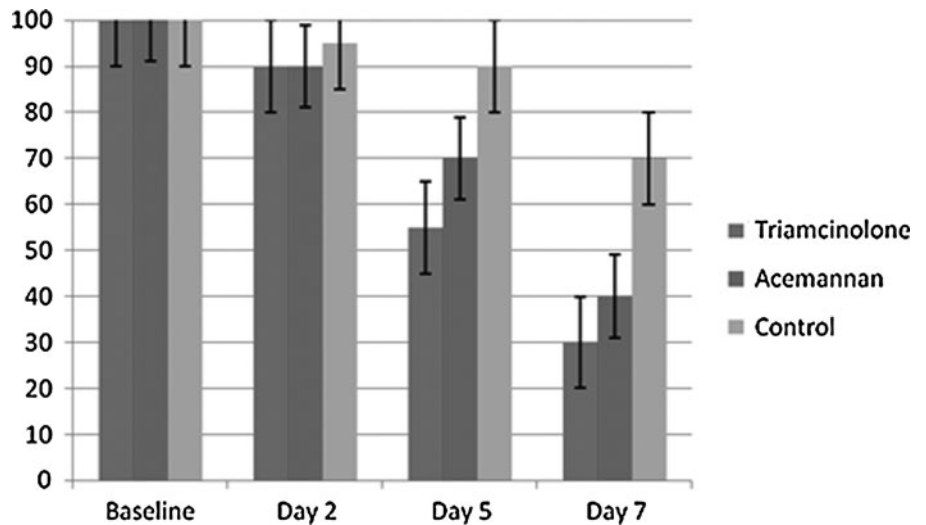


FIG. 4. Ulcer size reduction. Numbers represent percentages.



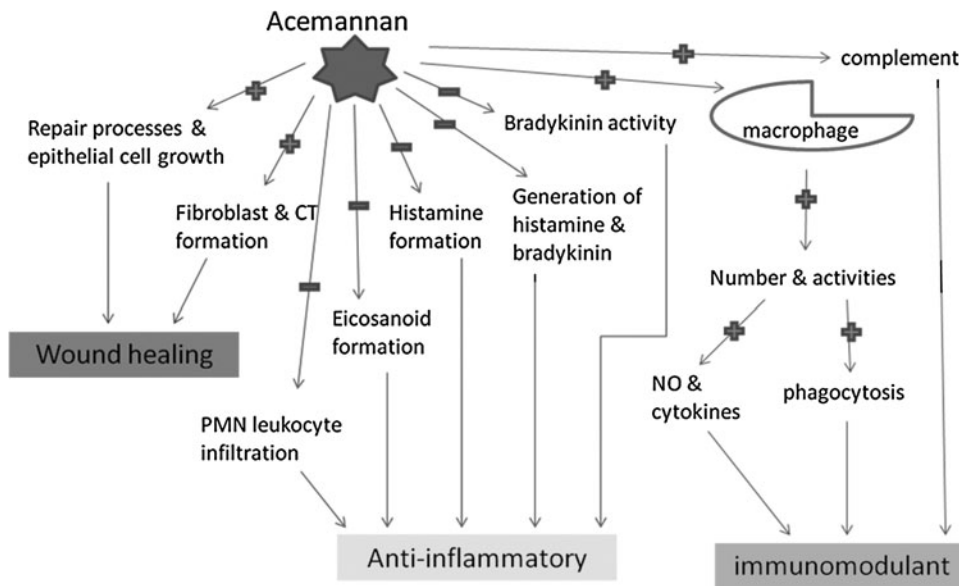


FIG. 5. Potential modes of action of acemannan. CT, connective tissue; PMN, polymorphonuclear.

human skin and oral mucosa. Acemannan was found to be effective in reducing the size of, and pain associated with, aphthous ulceration.

Ulcer size, pain level, and patient satisfaction of the medications applied in the treatment of oral aphthous ulceration were evaluated in this study. These are the main issues in the selection of medication for the treatment of RAU. The findings from the present controlled, randomized, double-blind study indicate that acemannan treatment reduced ulcer size and alleviated pain during the 7-day treatment regimen for MiRAU, although pain was not significantly reduced when compared to control. Interestingly, although subjects who used triamcinolone rated their satisfaction toward the medication higher than the ratings by the subjects who used acemannan, subjects who used all three medications preferred acemannan to triamcinolone. This could stem from a soothing feeling from the *Aloe vera* gel. The results of this study were not as dramatic as those reported by Sasithanasate et al. in 2008<sup>19</sup> and Jettanacheawchankit et al. in 2009<sup>16</sup> on the treatment of rat palatal wounds. The wounds made in those studies were larger (4mm) and improvements that were more obvious were found with acemannan treatment. Naturally occurring ulcers like RAUs tend to much smaller in size early in the lesion's time course than those created in these studies. Moreover, those studies were performed on rats' palates, which is not a characteristic site for RAUs. Since palatal mucosa is not movable, disturbances to the ulcers were much lower and this may have contributed to the more definitive outcomes they observed.

One limitation of the present study was the measurement of the ulcers. Since ulcer size reduction and pain relief are not the only signs of improvement of healing wounds, depth reduction and reduced levels of inflammation should also be measured. Thus, future study should create criteria for evaluation of these aspects as well.

The present study, to the authors' knowledge, is the first clinical trial using acemannan on recurrent aphthous ulcers. Although acemannan significantly reduced ulcer size, the precise mechanism whereby acemannan induces wound healing is still unknown. The effectiveness of acemannan in the

treatment of RAU that was observed in this study could be mediated through anti-inflammatory effects, wound healing promotion, and immunomodulation as shown in Figure 5.<sup>23</sup>

Based on the molecular weight and sugar structure of acemannan, acemannan could bind to a receptor on the cell surface and induce an intracellular signaling pathway.<sup>14</sup>

**Conclusions**

The present study indicates that acemannan can reduce recurrent aphthous ulcer size significantly more than control. While its effectiveness is not comparable to that of 0.1% triamcinolone acetonide, acemannan might be suitable for patients who wish to avoid the use of steroid medication.

**Acknowledgment**

This work (AS549A) was supported by the Higher Education Research Promotion and National Research University Project of Thailand, Office of the Higher Education Commission, and Government Research Fund. We would also like to extend our heartfelt gratitude to Dr. Kevin Tompkins for his assistance in reviewing this article.

**Disclosure Statement**

No competing financial interests exist.

**References**

1. Graykowski EA, Barile MF, Lee WB, Stanley HR. Recurrent aphthous stomatitis: Clinical, therapeutic, histopathologic, and hypersensitivity aspects. *JAMA* 1966;196:637-644.
2. Vincent SD, Lilly GE. Clinical, historic, and therapeutic features of aphthous stomatitis. *Oral Surg Oral Med Oral Pathol* 1992;74:79-86.
3. Scully C, Gorsky M, Lozada-Nur F. The diagnosis and management of recurrent aphthous stomatitis: A consensus approach. *JADA* 2003;134:200-207.
4. Lewkowicz N, Kur B, Kurnatowska A, et al. Expression of Th1/Th2/Th3/Th17-related genes in recurrent aphthous ulcers. *Arch Immunol Ther Exp (Warsz)* 2011;59:399-406.

5. Jurge S, Kuffer R, Scully C, Porter SR. Mucosal disease series: Number VI. Recurrent aphthous stomatitis. *Oral Dis* 2006; 12:1–21.
6. Cooke BE. Recurrent oral ulceration. *Br J Dermatol* 1969; 81:159–161.
7. Porter SR, Scully C, Pedersen A. Recurrent aphthous stomatitis. *Crit Rev Oral Biol Med* 1998;9:306–321.
8. Femiano F, Lanza A, Buonaiuto C, et al. Guidelines for diagnosis and management of aphthous stomatitis. *Pediatr Infect Dis J* 2007;26:728–732.
9. Barrons RW. Treatment strategies for recurrent aphthous ulcers. *Am J Health Syst Pharm* 2001;58:41–50.
10. Reynolds T, Dweck AC. Aloe vera leaf gel: A review update. *J Ethnopharmacol* 1999;69:3–37.
11. Chithra P, Sajithlal GB, Chandrakasan G. Influence of Aloe vera on collagen characteristics in healing dermal wounds in rats. *Mol Cell Biochem* 1998;181:71–76.
12. Vazquez B, Avila G, Segura D, Escalante B. Antiinflammatory activity of extracts from Aloe vera gel. *J Ethnopharmacol* 1996;55:69–75.
13. Strickland FM, Pelley RP, Kripke ML. Prevention of ultraviolet-induced suppression of contact and delayed hypersensitivity by *Aloe barbadensis* gel extract. *J Invest Dermatol* 1994;102:197–204.
14. Chithra P, Sajithlal GB, Chandrakasan G. Influence of aloe vera on the healing of dermal wounds in diabetic rats. *J Ethnopharmacol* 1998;59:195–201.
15. Femenia A, Sanchez ES, Simal S, Rossello C. Compositional features of polysaccharides from Aloe vera (*Aloe barbadensis* Miller) plant tissue. *Carbohydrate Polymers* 1999;39:109–117.
16. Jettanacheawchankit S, Sasithanasate S, Sangvanich P, et al. Acemannan stimulates gingival fibroblast proliferation; expressions of keratinocyte growth factor-1, vascular endothelial growth factor, and type I collagen; and wound healing. *J Pharmacol Sci* 2009;109:525–531.
17. Im SA, Lee YR, Lee YH, et al. *In vivo* evidence of the immunomodulatory activity of orally administered Aloe vera gel. *Arch Pharm Res* 2010;33:451–456.
18. Fogleman RW, Shellenberger TE, Balmer MF, et al. Subchronic oral administration of acemannan in the rat and dog. *Vet Hum Toxicol* 1992;34:144–147.
19. Sasithanasate S, Jettanacheawchankit P, Sangvanich P, et al. Accelerating Effects of the Acemannan Extract on Wound Healing of Rat Palatal Mucosa. Bangkok: The 15th Congress of FAVA -OIE Joint Symposium on Emerging Diseases, 2008.
20. Ni Y, Turner D, Yates KM, Tizard I. Isolation and characterization of structural components of Aloe vera L. leaf pulp. *Int Immunopharmacol* 2004;4:1745–1755.
21. Tai-Nin Chow J, Williamson DA, Yates KM, Goux WJ. Chemical characterization of the immunomodulating polysaccharide of *Aloe vera* L. *Carbohydr Res* 2005;340:1131–1142.
22. Jittapiromsak N, Jettanacheawchankit S, Lardungdee P, et al. Effect of acemannan on BMP-2 expression in primary pupal fibroblasts and periodontal fibroblasts, *in vitro* study. *J Oral Tissue Engin* 2007;4:149–154.
23. Lex MC. Biological Activities of Acemannan. Online document at: [www.symmetrydirect.com/pdf/BioActivofAcemannan.pdf](http://www.symmetrydirect.com/pdf/BioActivofAcemannan.pdf) Accessed February 15, 2012.

Address correspondence to:

Kanokporn Bhalang, PhD

Department of Oral Medicine

Faculty of Dentistry

Chulalongkorn University

Henri Dunant Road

Wangmai, Pathumwan, Bangkok 10330

Thailand

E-mail: Kanokporn.Bh@chula.ac.th

Copyright of Journal of Alternative & Complementary Medicine is the property of Mary Ann Liebert, Inc. and its content may not be copied or emailed to multiple sites or posted to a listserv without the copyright holder's express written permission. However, users may print, download, or email articles for individual use.