

# Experience with Alpha-Lipoic Acid plus Low-Dose Naltrexone (ALA/N) for various cancers and autoimmune disease.

Invitational Lecture National Cancer Institute  
2012  
and  
2013 LDN Conference  
Harper College  
Palatine, Illinois

Burton M. Berkson MD MS PhD  
President, the Integrative Medical Center of New Mexico  
1155 Commerce Drive  
Las Cruces, New Mexico, 88011  
Former Professor Rutgers University and Chicago State University  
and Adjunct Professor NMSU  
bberkson@nmsu.edu

## Low Dose Naltrexone plus Alpha Lipoic Acid

- Not a cure for cancer, however, some people do very well for long periods of time and some don't have any tumor progression.
- And some tumors go dormant and don't show up on PET scans years after terminal diagnosis by conventional therapists.

## Low Dose Naltrexone (LDN)

- 3.0 to 4.5 mg at bedtime causes Endorphin/enkephalin blockade.
- In morning there is a flood of endorphins and enkephalins etc.
- Cancer cells have enkephalin receptors that slow cellular growth.
- Several papers (Plotnikoff NP, Zagon I etc.) have shown that increased met-enkephalin (opiate growth factor, OGF) production slows the growth of cancer cells by attaching to their receptors.

-Low-dose naltrexone may reverse the development of tolerance of opioids by its binding to filamin A (cell cytoskeleton).

-Endogenous opioids are known to produce analgesia. An increase in endogenous opioids through LDN use may result in less pain.

-LDN binds to Toll-Like Receptor 4 (TLR4 activates innate immune cells), thus blocking inflammatory Lipopolysaccharides (LPS). This action prevents the LPS from producing inflammation.

# BARTTER AND BERKSON et al PAPERS

In the late 1970's Dr. FC Bartter and I treated 79 patients with Acute Hepatic Necrosis at various medical centers across America.

75 regenerated their livers using just intravenous Alpha-Lipoic Acid (Thioctic Acid)



Amanita verna

# Longtime picker meets match in mushroom patch

By Karen R. Long

Gregg Finohr swears he'll never do it again.

Finohr, an 11-year veteran of mushroom-picking who usually hunts carefully with a field guide, entered Mount Sinai Hospital last Friday with severe mushroom poisoning. He still has muscle cramps but is grateful to be alive.

"God, I'll never eat them again," he said. "This is just crazy. I can't believe this happened."

Finohr, 28, nearly died after eating between 10 and 14 wild mushrooms he assumed were related to the edible pinky-cap species.

"I stopped at a field out by Avon Lake to kill some time," he said yesterday from his hospital bed. "I noticed a lot of mushrooms around. I usually have a field guide with me, but I didn't this time. I picked a quantity, went home, cleaned and stored them, eating a few while I cleaned. The next morning I ate a few more from the refrigerator and that's when I got sick."

Finohr, of 13988 Clifton Blvd., Lakewood, did not make the common mistake of thinking he had the flu. He called the Poison Control Center

poisoning specialist, Dr. Burton M. Berkson.

Berkson did not pump Finohr's stomach.

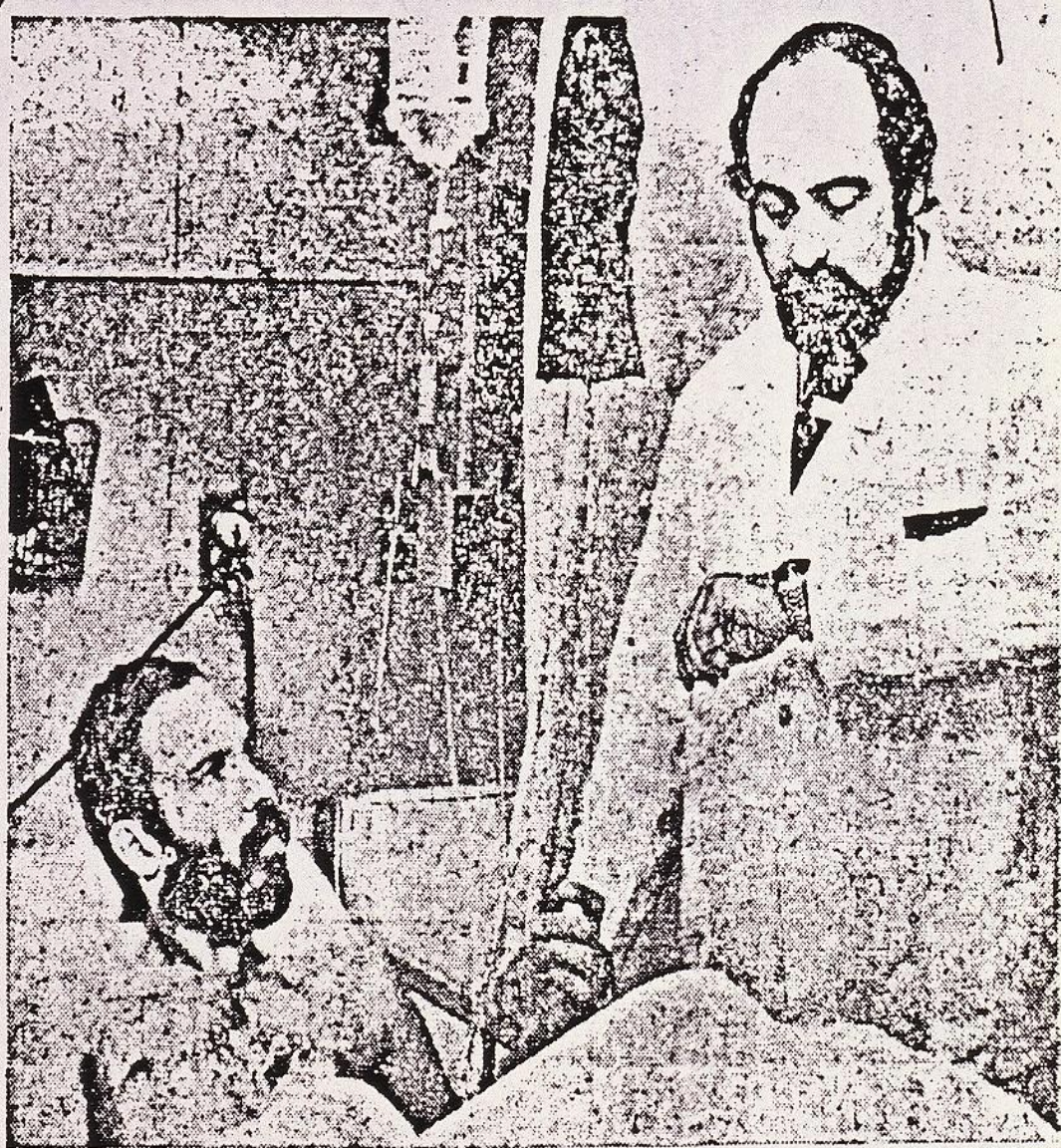
"He didn't get sick until 16 hours after eating them," the doctor said. "By that time all the poison was absorbed. I gave him an antibiotic to bind (deactivate) any unbound toxins which might still be in his bloodstream."

Berkson, who has a doctorate in mycology, the study of fungi, believes Finohr ate a member of the genus *Cortinarius*. He ordered a special drug, thioctic acid, to be flown in from Washington, D.C.

The characteristics of mushroom poisoning are divided into four stages. Finohr suffered the first two before his thioctic acid treatments began Saturday.

The first stage is a period of well-being, lasting 12 to 36 hours. The second is similar to stomach flu, with diarrhea and vomiting, and lasts one or two days. The third stage is apparent recovery, when the doctor may think the patient is better. The last phase is hepatic coma and sometimes death.

Cleveland had one death from



The Plain Dealer/Charles

cases last year.

This is the season for mushroom picking — a pastime that Berkson said is especially popular in Greater Cleveland. His advice is to refrain. "But I have the feeling people aren't going to avoid them, so it's best if they know the mushroom characteristics well."

species of the genus that poisoned Finohr.


The young construction worker said he hopes others take note of his ordeal. He said he was "very grateful Dr. Berkson knows what he does. I'd read about it (the danger) but I never thought it would happen to me —

Dr. Burton Berkson checks the pulse of mushroom picker Gregg Finohr, a victim of mushroom poisoning.



FC Bartter MD (Chief NIH),  
Barry Rumack MD and  
Burt Berkson MD MS PhD as visiting  
Scientists at the Max Planck Institute in  
Heidelberg, Germany 1978

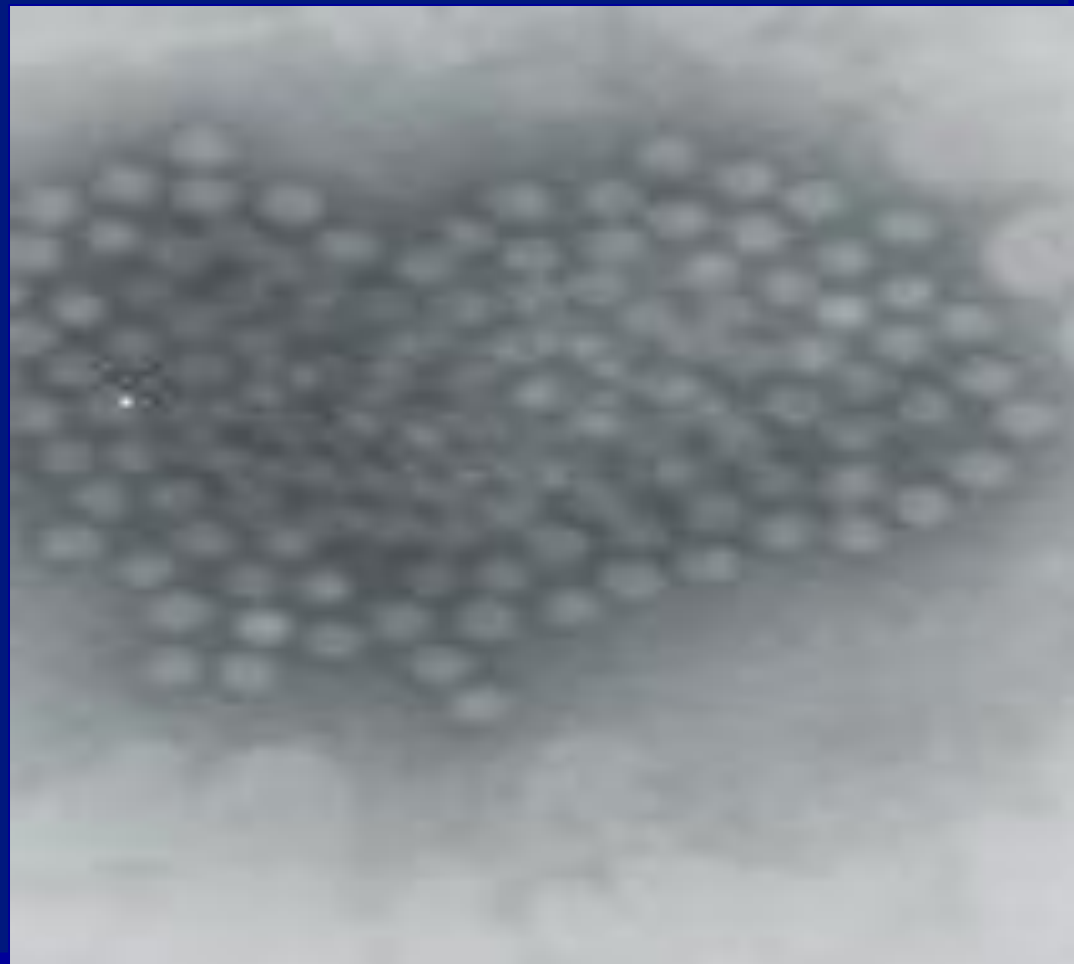




# THIOCTIC ACID IN THE TREATMENT OF POISONING WITH ALPHA-AMANITIN

Bartter FC, Berkson B, Gallelli P, Hiranaka P 1980, Amanita Toxins and Poisoning, eds Faulstich et al, Verlag Gerhard Witzstrock, Baden-Baden, New York

title should have been  
lipoic acid reverses acute  
liver damage.



Berkson BM.


*A conservative triple  
antioxidant therapy for  
hepatitis C.*

*Combination of alpha lipoic  
acid (thioctic acid),  
selenium, and silymarin*

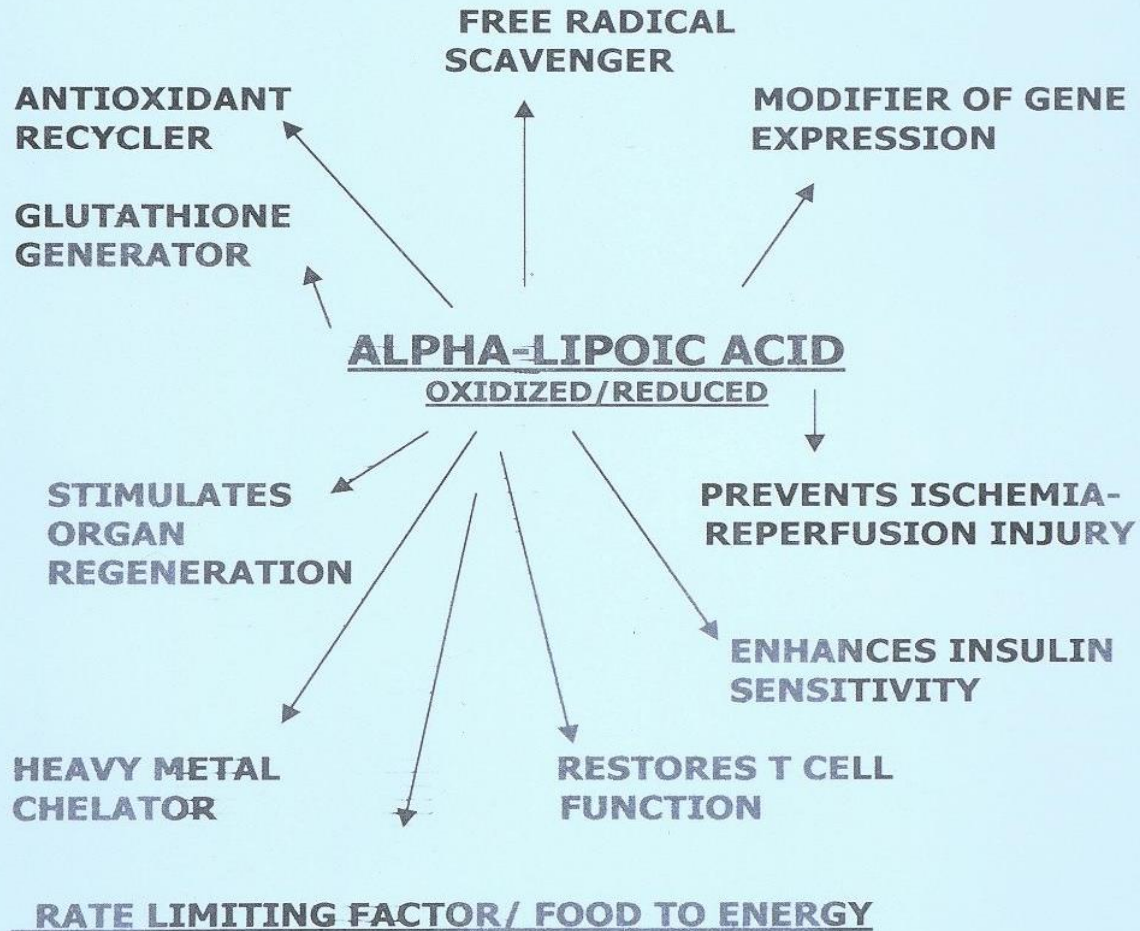
Med Klin (Munich). 1999 Oct 15;94 Suppl  
3:84-9. A

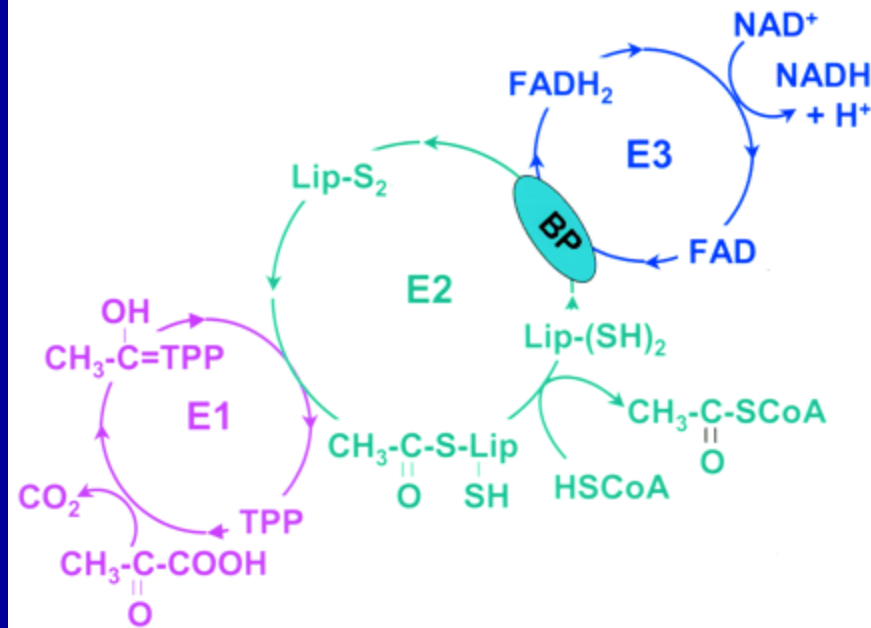
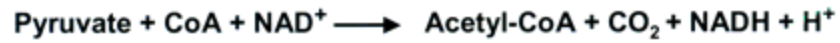






# ACTIONS OF ALA





Pyruvate Dehydrogenase Complex



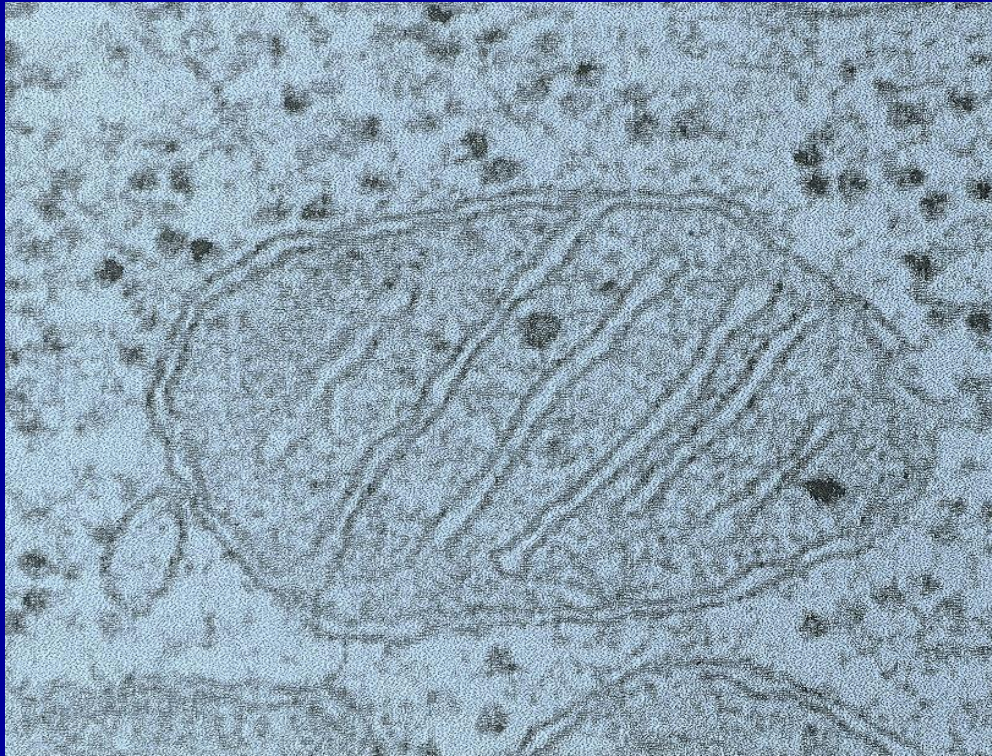
What about ALA and cancer?

Cancer cells hate oxygen.

Warburg O. The chemical constitution of respiration ferment. *Science*.

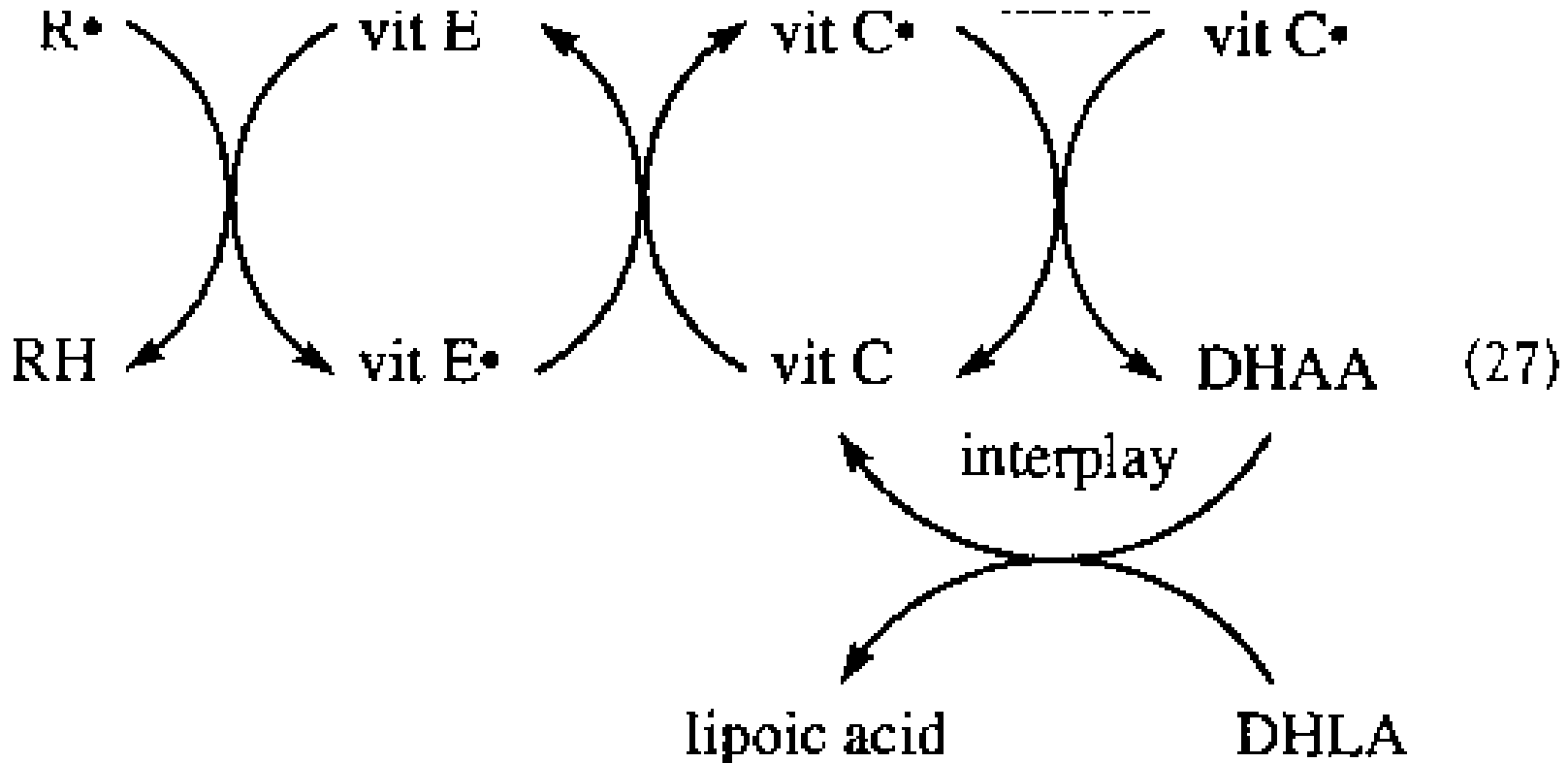
1928;68:437–443. doi: 10.1126/science.68.1767.437.

# Healthy primate mitochondrion

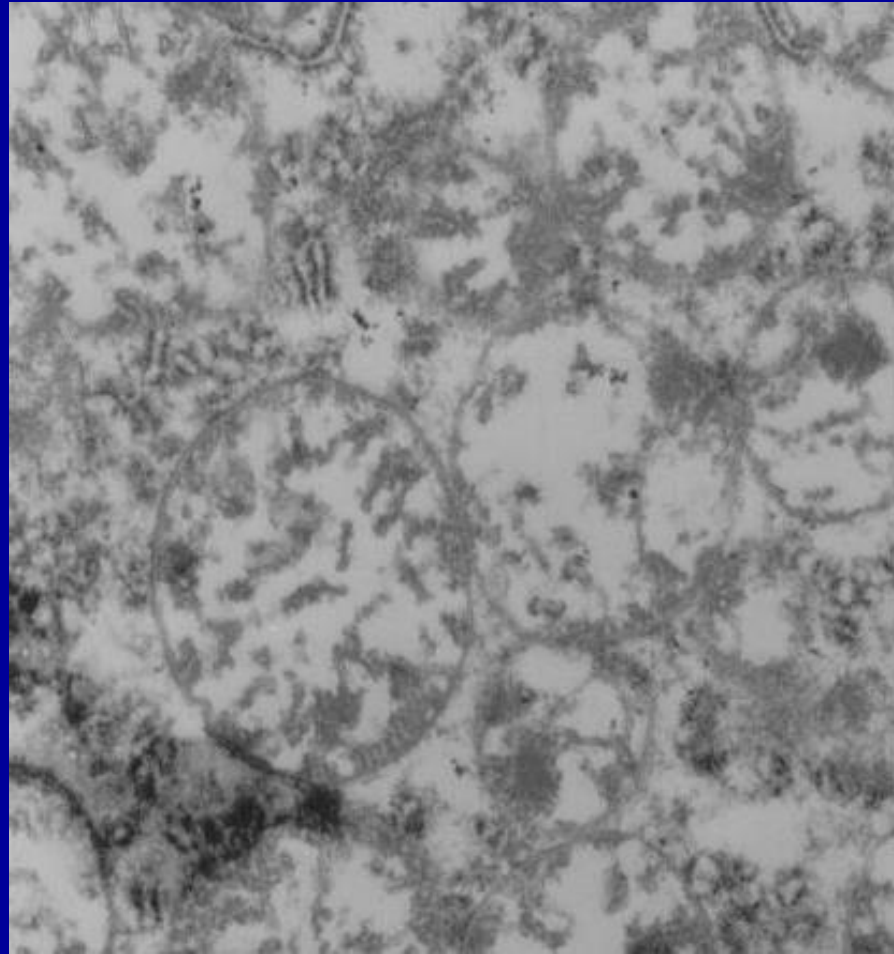


# ALPHA-LIPOIC ACID RECYCLES OTHER IMPORTANT ANTIOXIDANTS

Biewenga, 1997



Primate mitochondria following LD50 studies  
About 90mg/kg



**LIVER MITOCHONDRIA SUFFERED SEVERE STRUCTURAL  
DAMAGE BY EXTREMELY HIGH DOSES OF INTRAVENOUS  
ALPHA LIPOIC ACID**

in press Global Advances in Health and Medicine 2013

**Michael Vigil MD**

Former Adjunct Associate Research Professor, Department of Biochemistry  
NMSU

**Burton M. Berkson MD MS PhD**

Former Assistant Professor, Rutgers University  
Former Associate Professor, Chicago State University  
President, The Integrative Medical Center of New Mexico  
Adjunct Professor, NMSU  
bberkson@nmsu.edu  
(corresponding author)

**Ana Patricia Garcia DVM MS PhD**

Associate Research Professor and Veterinary Pathologist Yerkes  
Assistant Professor, Department of Pathology and Laboratory Medicine  
Emory University School of Medicine

Lipoic disrupts cancer cell mitochondrial metabolism and is potent anticancer agents in vivo.

Zachar Z, Marecek J, et al

J Mol Med (Berl). 2011 Nov;89(11):1137-48. Epub 2011 Jul 19.

Lipoic acid disrupts tumor mitochondrial metabolism and is followed by cell death by apoptosis and necrosis with low side-effect toxicity.

Alpha-Lipoic acid induces apoptosis in human colon cancer cells by increasing mitochondrial respiration which results in O<sub>2</sub><sup>-\*</sup>-generation.

Wenzel U, Nickel A, and Daniel H.  
Apoptosis. 2005 Mar;10(2):359-68

This study provided evidence that ALA can induce cancer cell death by a prooxidant mechanism that is initiated by an increased uptake of oxygen into the mitochondrion.

# Antiproliferative effects of $\alpha$ -lipoic acid in human colon cancer cells in vitro.

Kono Y, Inomata M, Hagiwara S, et al.

Expert Opin Ther Targets. 2012 Mar;16 Suppl 1:S103-9. Epub 2012 Feb 8.



**Alpha-lipoic acid** induces apoptosis in tumor cell lines and no apoptosis in normal cell lines.

van de Mark K, Chen JS, Steliou K, Perrine SP, Faller DV.

J Cell Physiol. 2003 Mar;194(3):325-40.

The differential selectivity of the pro-apoptotic effects of alpha-lipoic acid for cancer cells supports its potential use in the treatment of cancer

# Alpha-lipoic acid induces apoptosis and necrosis in hepatocellular carcinoma cells.

Shi DY, Liu HL, Stern JS, Yu PZ, Liu SL.

FEBS Lett. 2008 May 28;582(12):1667-71.

Na MH, Seo EY, Kim WK Nutr Res Pract. 2009 Winter;3(4):265-71.

**Alpha-lipoic acid stimulates apoptosis in human breast cancer cells.**

and

Choi SY, Yu JH, Kim H. Ann N Y Acad Sci. 2009 Aug;1171:149-55.

**Alpha-lipoic acid induces apoptosis of lung cancer cells.**

## Lipoic Acid Plus Low-Dose Naltrexone Reviewed for Cancer Treatment

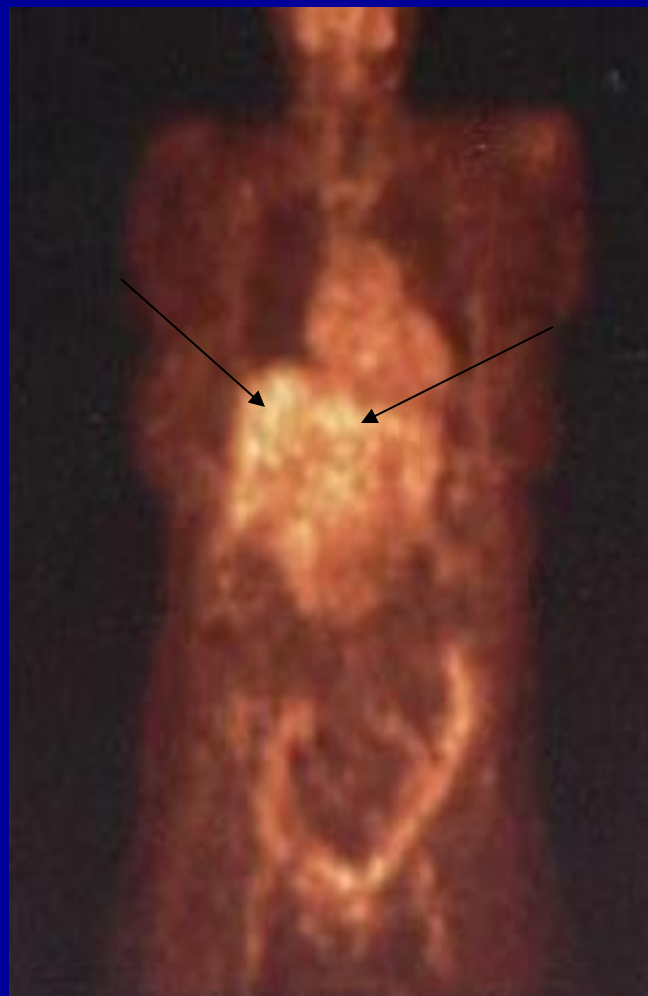
- NCI staff and invited guests listen to **Drs. Berkson and Donahue** discuss their research and treatments on March 19, 2012
- A panel of researchers and clinicians was convened by the National Cancer Institute (NCI) for presentations and a roundtable discussion about “**The State of the Science of Alpha-Lipoic Acid plus Low-Dose Naltrexone for the Treatment of Cancer.**” The meeting was hosted by the Cancer Therapy Evaluation Program (CTEP), both part of the NCI Division of Cancer Treatment and Diagnosis (DCTD). The meeting provided an opportunity for NCI staff and outside experts to review and discuss case reports from **Dr. Burton M. Berkson**, an integrative medicine physician and Ph.D. in Biological Sciences, and Adjunct Professor at New Mexico State University. Dr. Berkson presented on his experience treating patients with alpha-lipoic acid (ALA) plus low-dose naltrexone (LDN) for various cancers and autoimmune diseases. The group also heard from **Dr. Renee N. Donahue**, Research Fellow in the Laboratory of Tumor Immunology and Biology at the NCI Center for Cancer Research, about her pre-clinical research on the efficacy and proposed mechanism of action of LDN for the treatment of cancer. Dr. Farah Zia, Director of OCCAM’s Case Review and Intramural Science Program, noted, “The cases being presented today by Dr. Berkson were submitted and given rigorous scientific evaluation under the NCI Best Case Series (BCS) protocol. The ultimate goal of the BCS is to identify those complementary and alternative medicine (CAM) interventions that have enough evidence to support NCI-initiated research.”. with a combination of ALA (intravenously and orally) and LDN (orally), along with diet, vitamins, and lifestyle changes. Earlier in his medical career, Dr. Berkson reported success using ALA to repair liver damage in patients from mushroom poisoning or chronic infections with hepatitis C virus. He also cited a number of research articles in European medical journals showing ALA’s beneficial effects on cancer.

PRIMARY HEPATOCELLULAR CARCINOMA

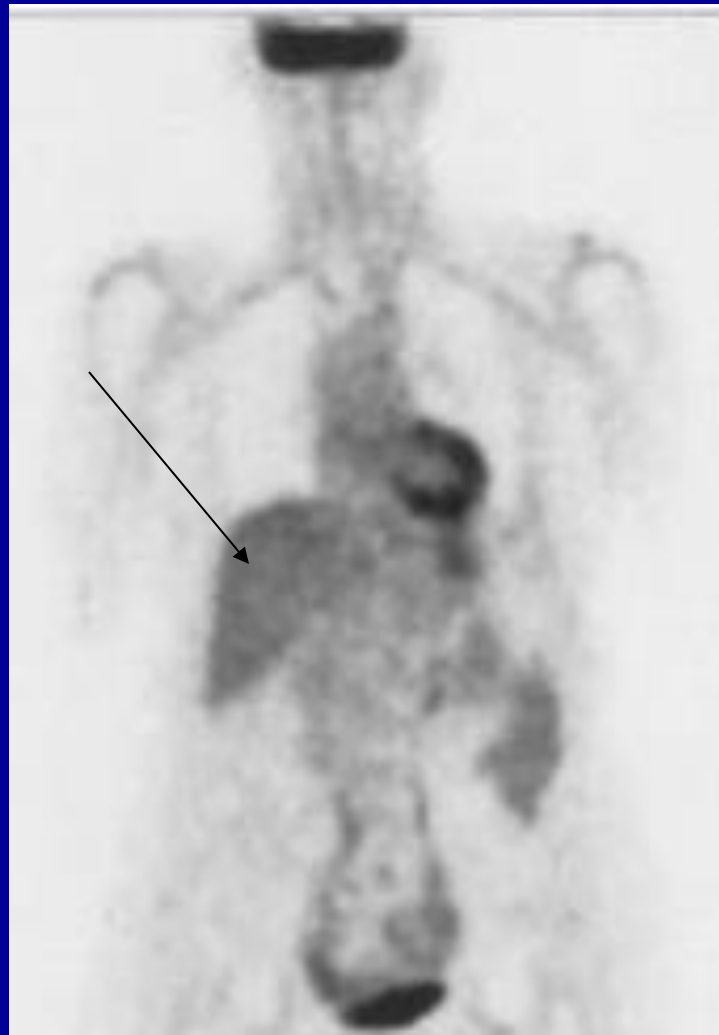
Mrs. JAL

60 year old RN

MRS JAL OCTOBER, 2006



MRS JAL JANUARY 2009



## B-CELL LYMPHOMA

Mrs. TES

47 year-old med. Tech.

Severe RA first visit

Treated with ALA/N

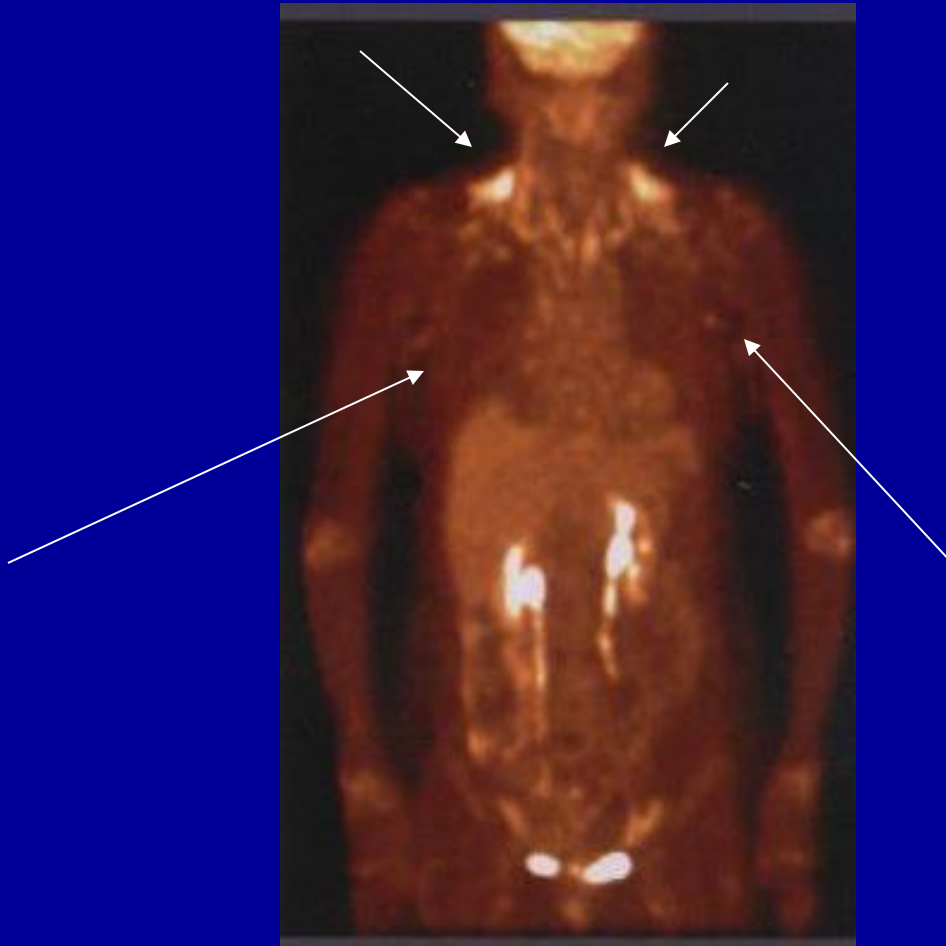Improved

Rheumatologist prescriber Humira

She developed B-cell lymphoma



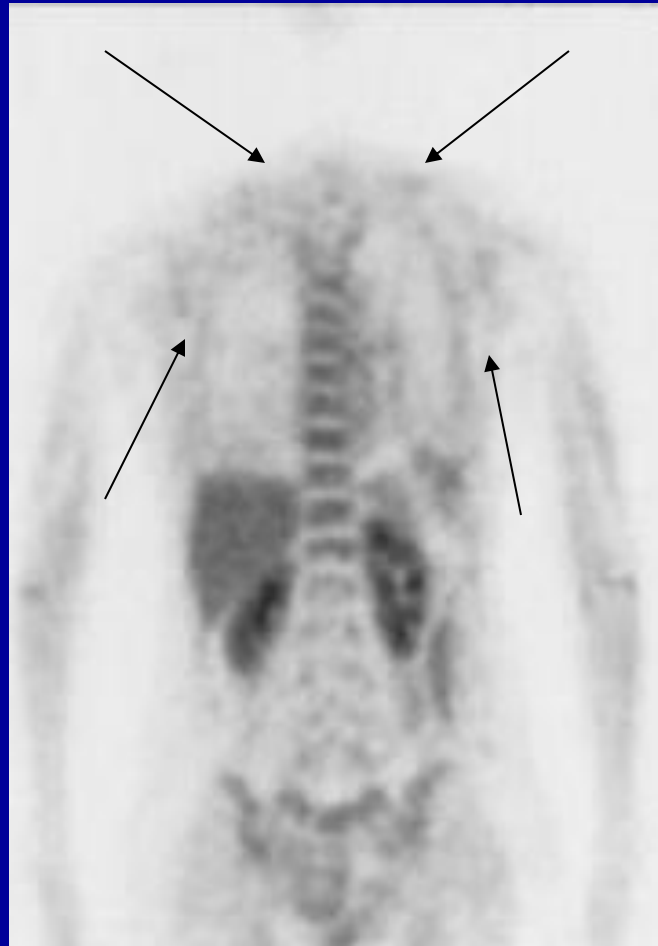MRS T ES  
PET/CT APRIL 2008

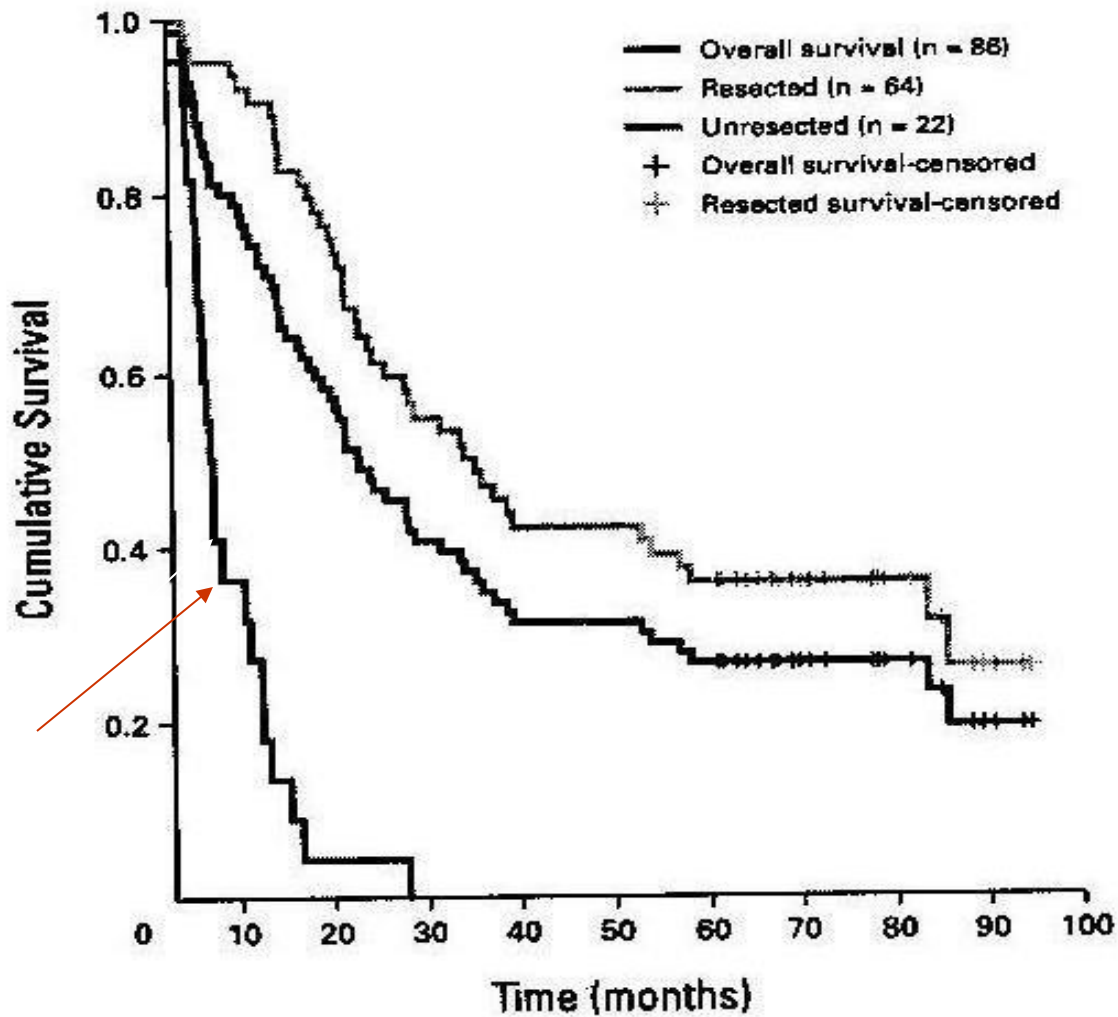


# MRS TES

- Off Humira
- Enlarged lymph nodes did not disappear
- Back on ALA/N

MRS T ES  
PET/CT SEPTEMBER 2009





Pancreatic Cancer Survival Curve  
MD Anderson Hospital 2008

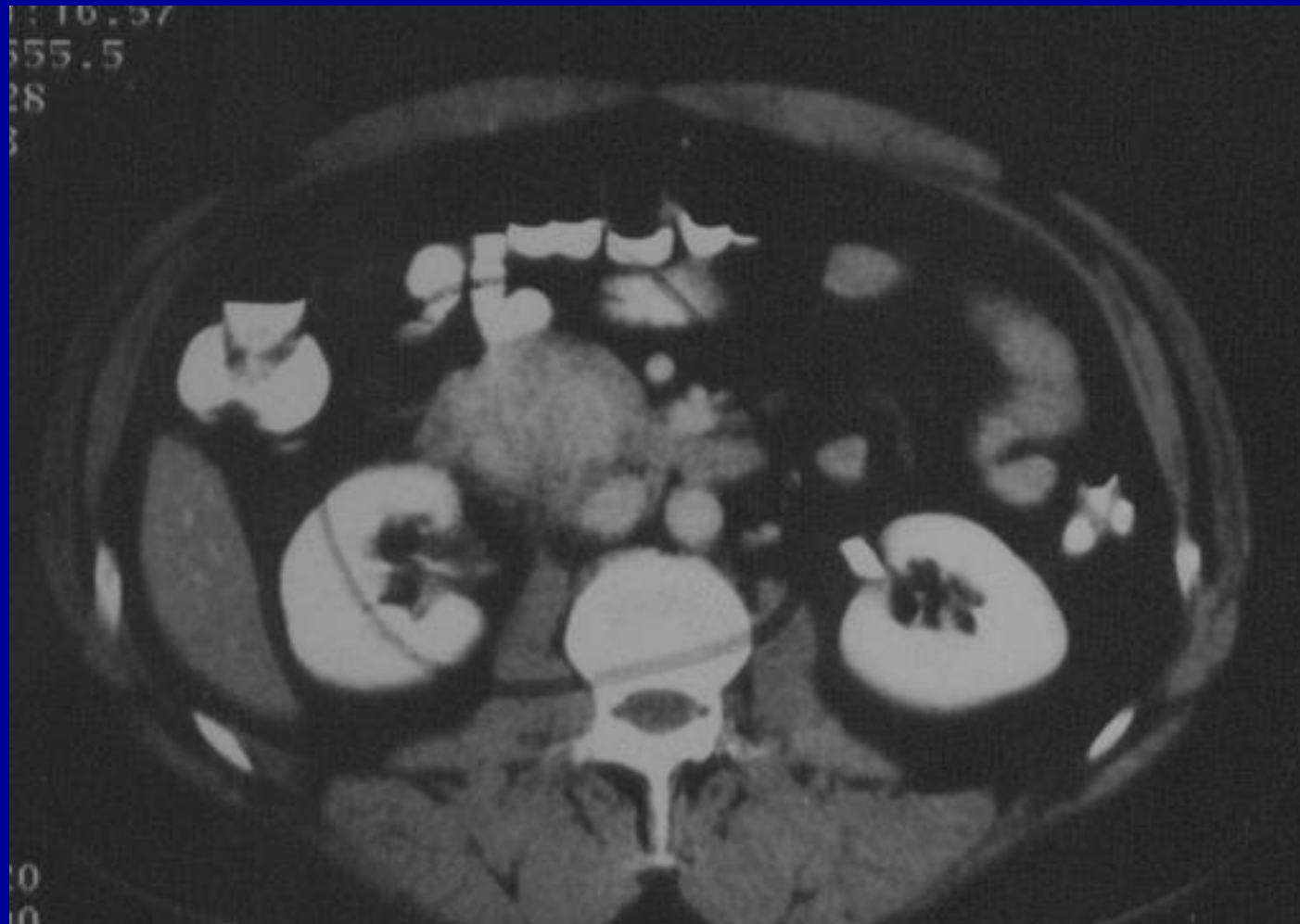“The long-term survival of a patient with  
pancreatic cancer and metastases to the liver”

Berkson BM, Rubin DM, and Berkson AJ  
Integrative Cancer Therapies  
Volume 5, Number 1, March 2006

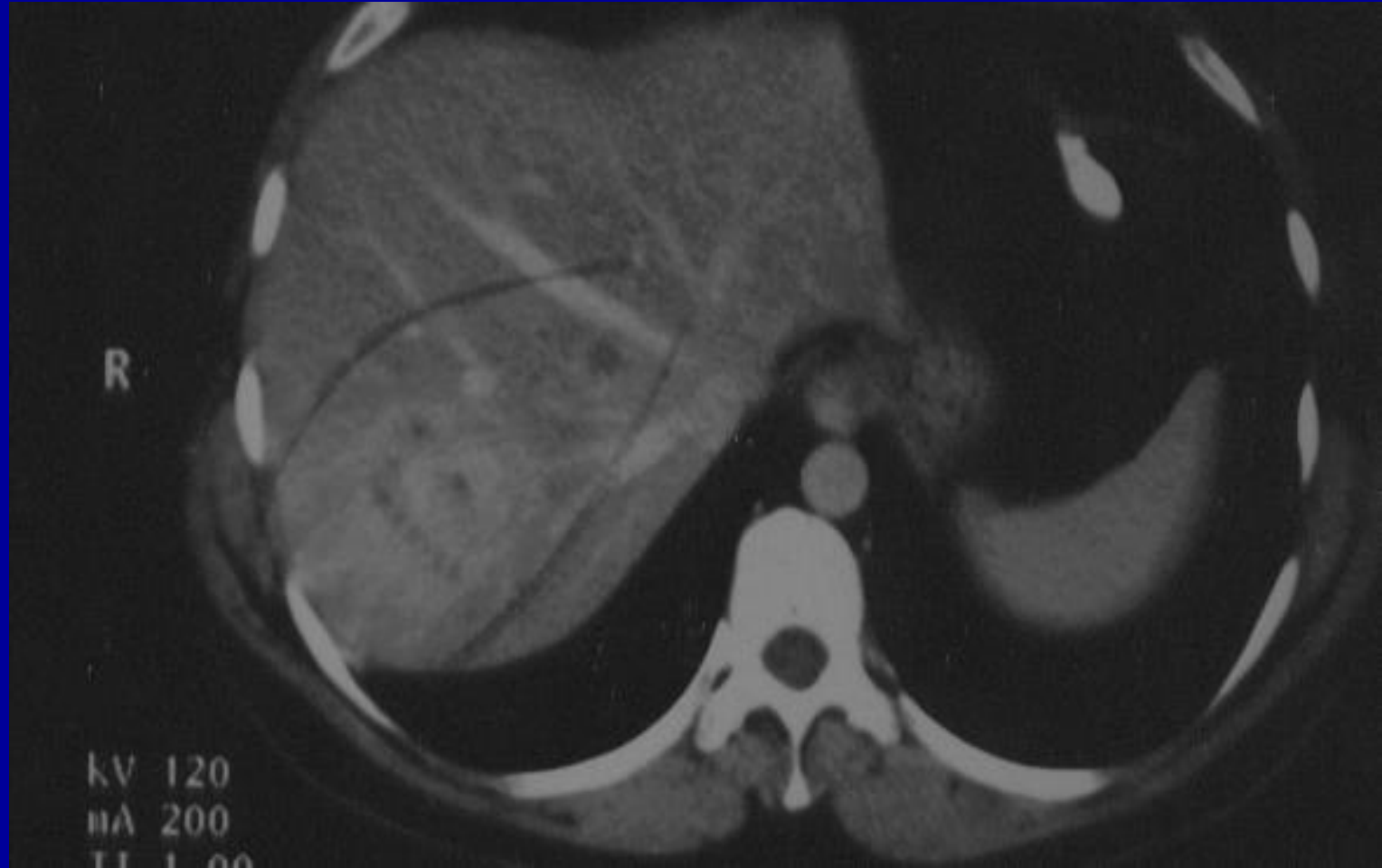
## Mr. JA

- 46 year-old male from New Mexico.
- Presented to the ER with vague abdominal pain, Oct, 2002.
- CT revealed a dense mass in the head of the pancreas and at least 3 lesions in the liver.
- Fine needle biopsy of the liver metastasis revealed a poorly differentiated adenocarcinoma.

OCTOBER 8, 2002



OCTOBER 8, 2002





## MR. JA NOVEMBER 2002

- Following diagnosis JA was sent to an oncologist for chemotherapy.
- He received a 21 day course of gemcitabine and carboplatin.
- JA became very leukopenic and thrombocytopenic.
- The oncologist stopped therapy and offered no hope for survival.

## MR JA NOVEMBER 2002

- JA sought a second opinion from MD Anderson Hospital
- After a work-up and review of records and biopsies, the patient was told that his condition was hopeless and he should go to hospice.

NOVEMBER 25, 2002

- JA presented to my office and told me that he had a young son and did not want to die.
- I told him that I was not an oncologist, however, I would try to find a protocol that might prolong his life.

# MR. JA MEDICAL PROGRAM

- Diet, nutritional, and palliative support.
- Prescription drugs.
- Modulation of immunity.

# JA'S PROTOCOL

Healthy life-style program.

Low dose naltrexone 4.5 mg qhs

Alpha-lipoic acid IV and PO and B-complex vitamins.

Alprazolam 0.25 qhs prn.

Cimetidine 300 mg. qhs.

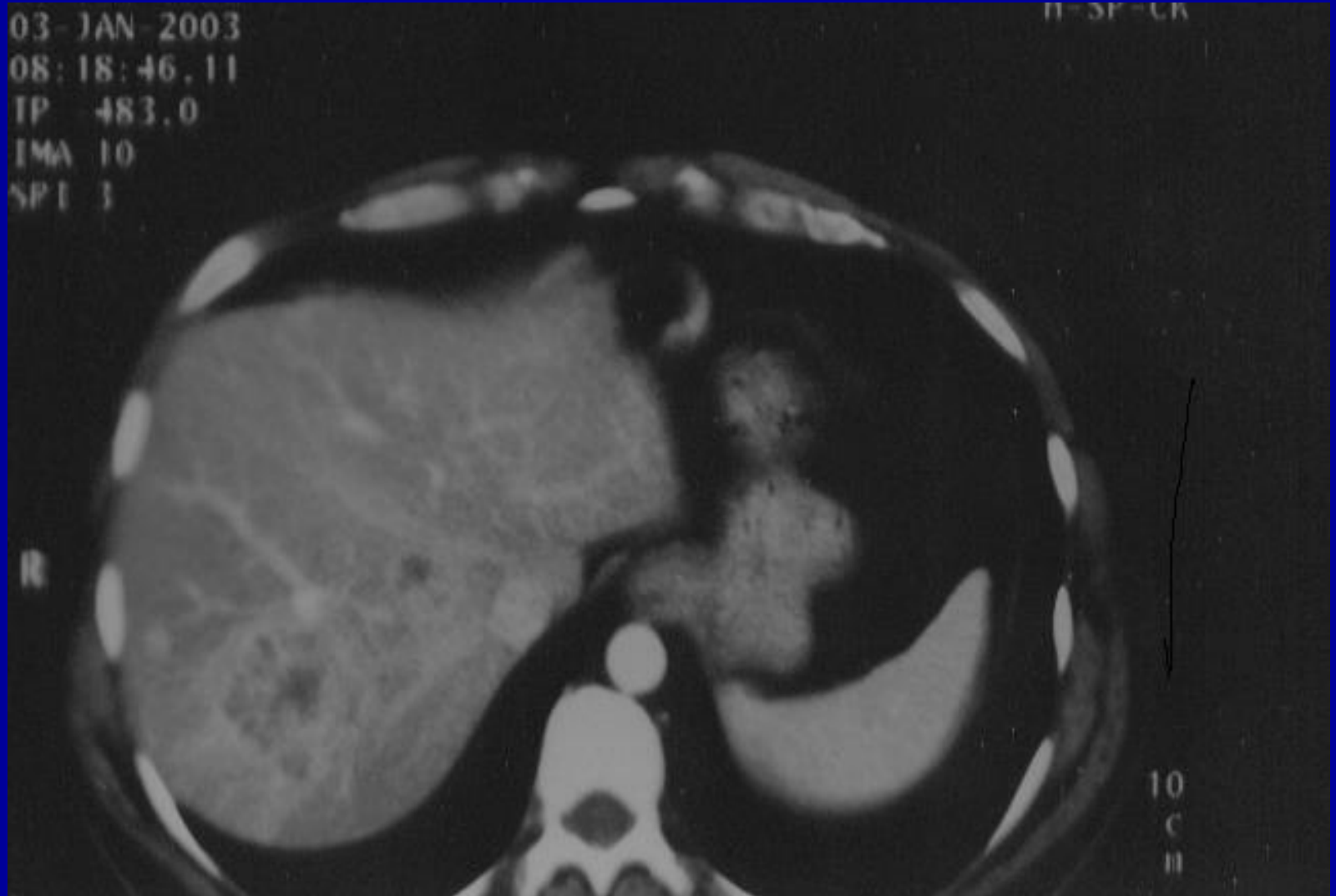
## MR. JA AFTER SECOND WEEK OF TREATMENT

- “I’m beginning to feel normal again.”
- On January 3, 2003, A repeat CT was performed.  
(3 months following diagnosis)

# JANUARY 3, 2003 STABLE HEPATIC LESIONS

03 - JAN - 2003  
08:18:46.11  
TP 483.0  
IMA 10  
SPL 1

11-3P-CR

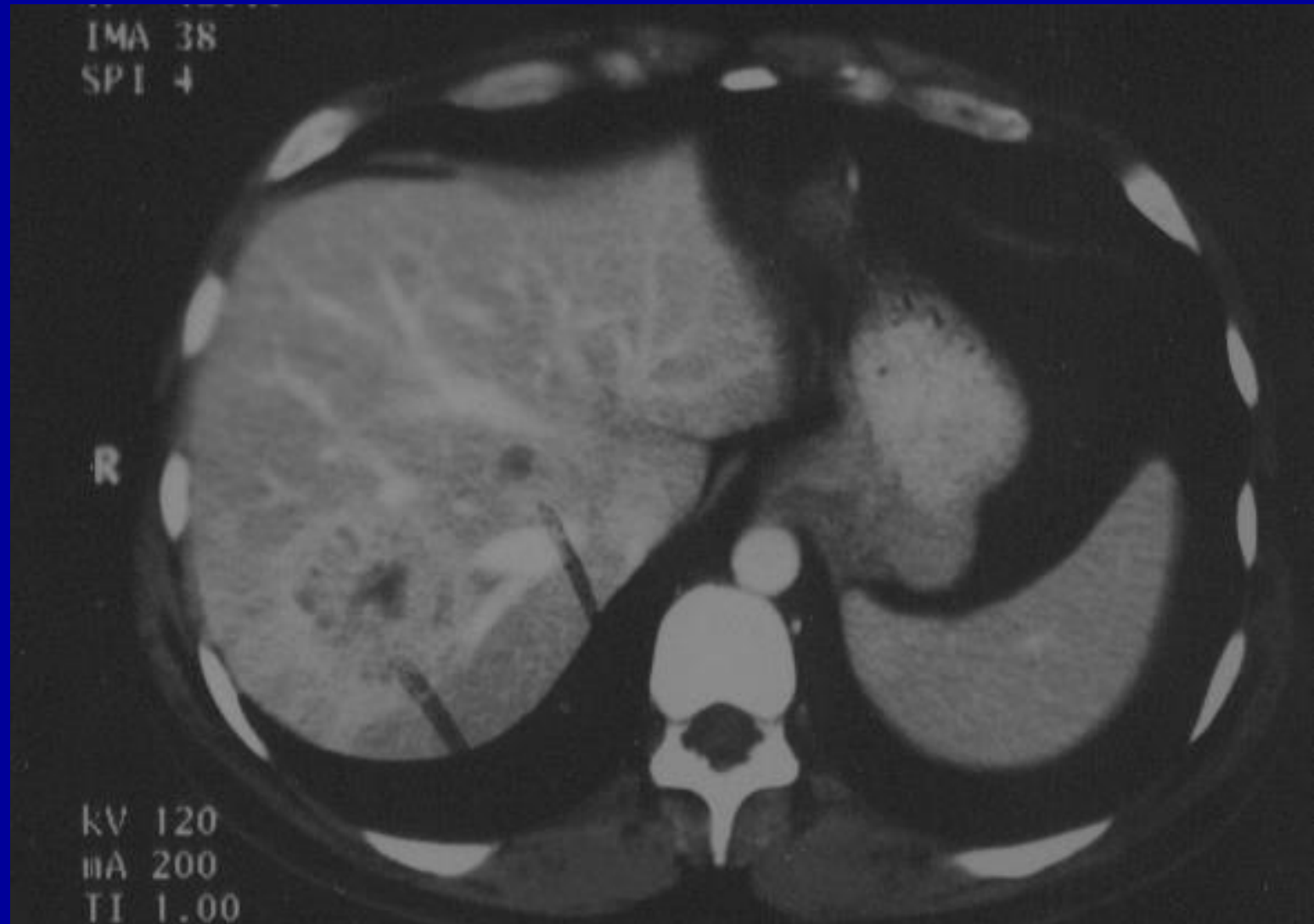

## MR. JA

- The course of events were uneventful.
- JA went back to work full-time feeling normal (January, 2003)



FEBRUARY 24, 2003  
STABLE HEPATIC LESIONS



## MR TA

- As TA continued his treatment plan, he wanted follow up CT scans at regular intervals.
- The CT's revealed no significant changes.

FEBRUARY, 2006  
40 MONTHS POST DX

CT: ABDOMEN (AXIAL)

ACQ:

Se: 3/3

2006 Feb 15

Im: 36/2

1:24:28.000

Ax: 1231.2

512 x 512  
STANDARD

R

L

120.0 kV

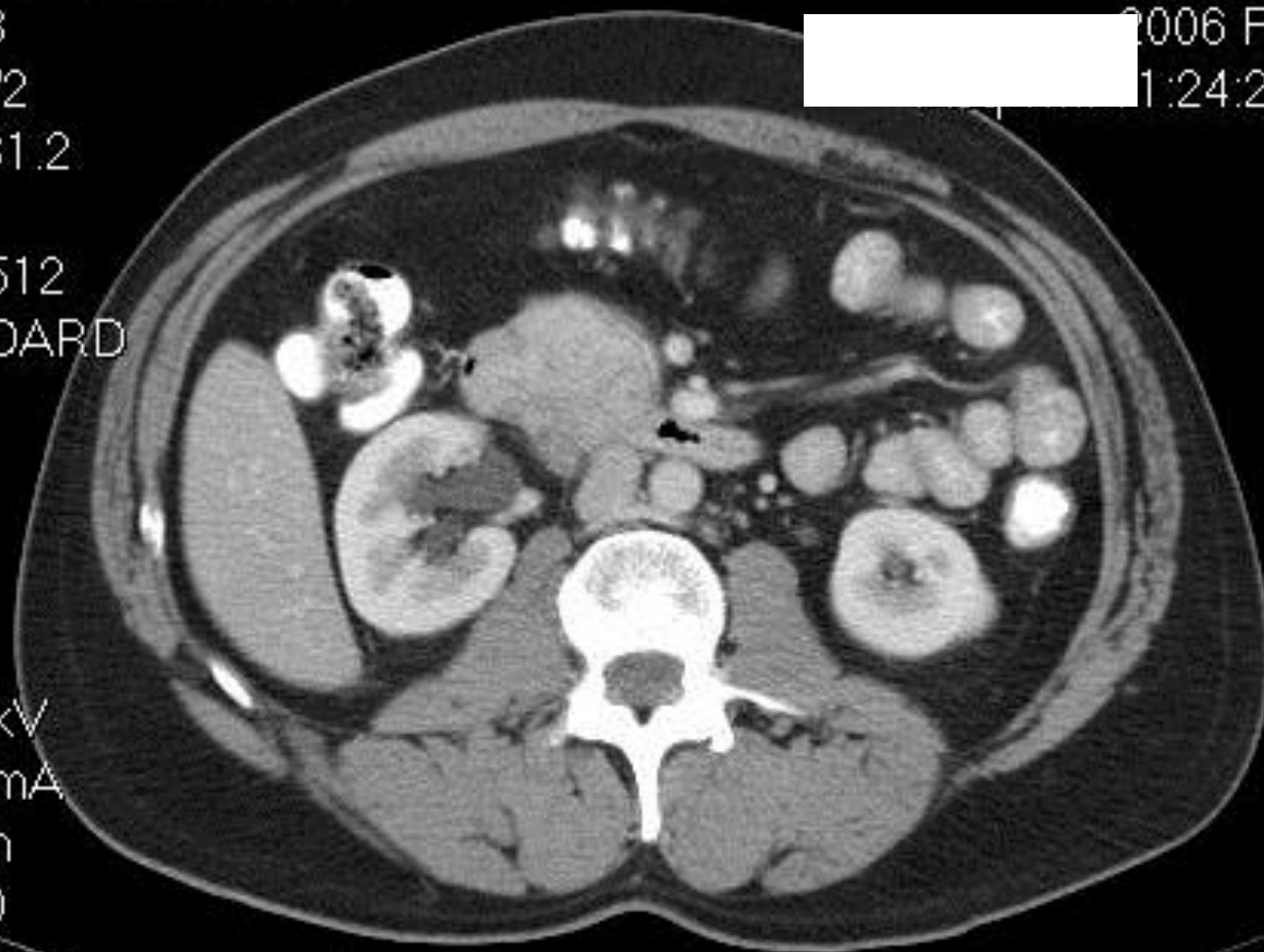
386.0 mA

5.0 mm

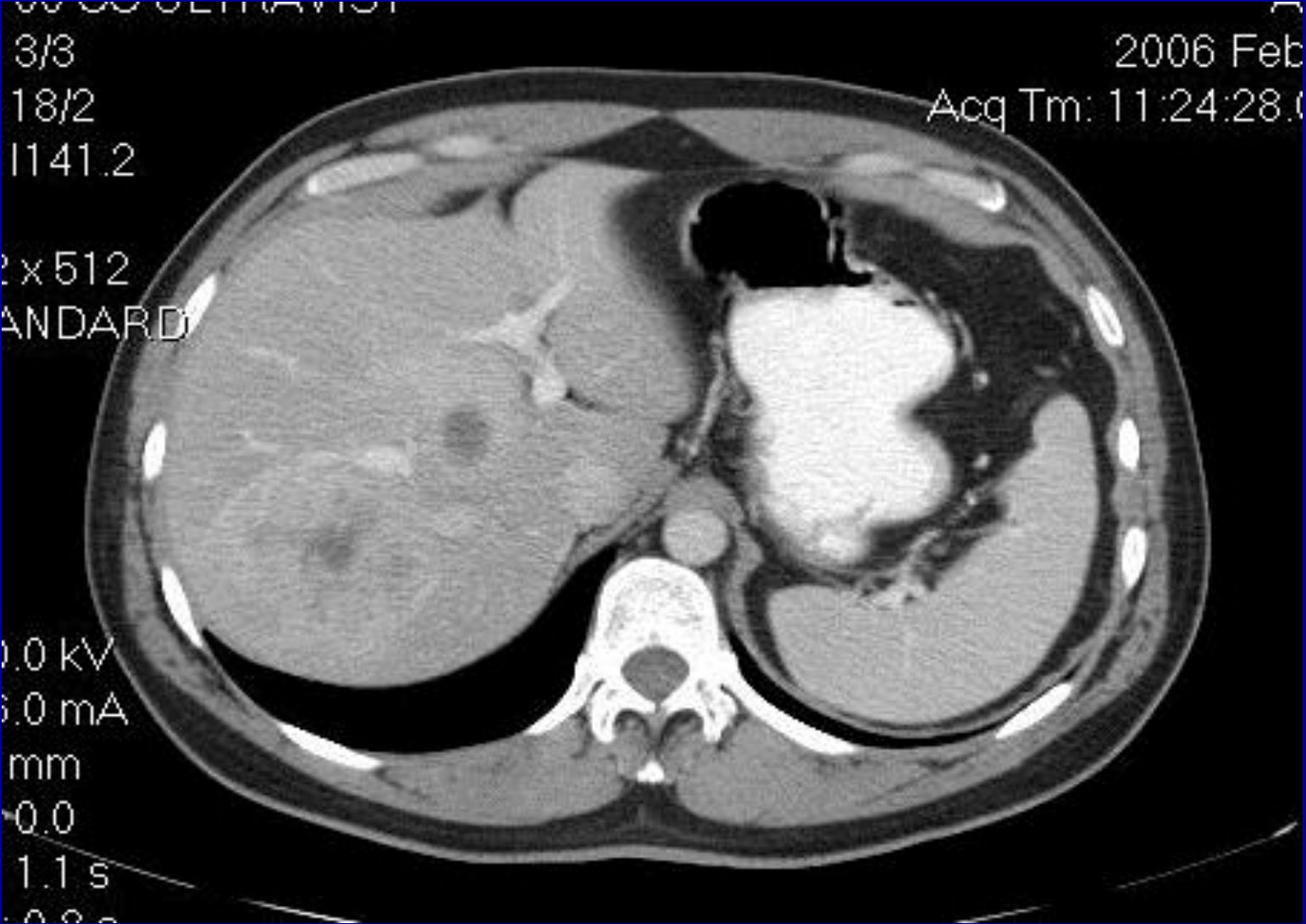
Tilt: 0.0

ET: 1.1 s

CD: 0.0 s



FEBRUARY, 2006  
40 MONTHS POST DX

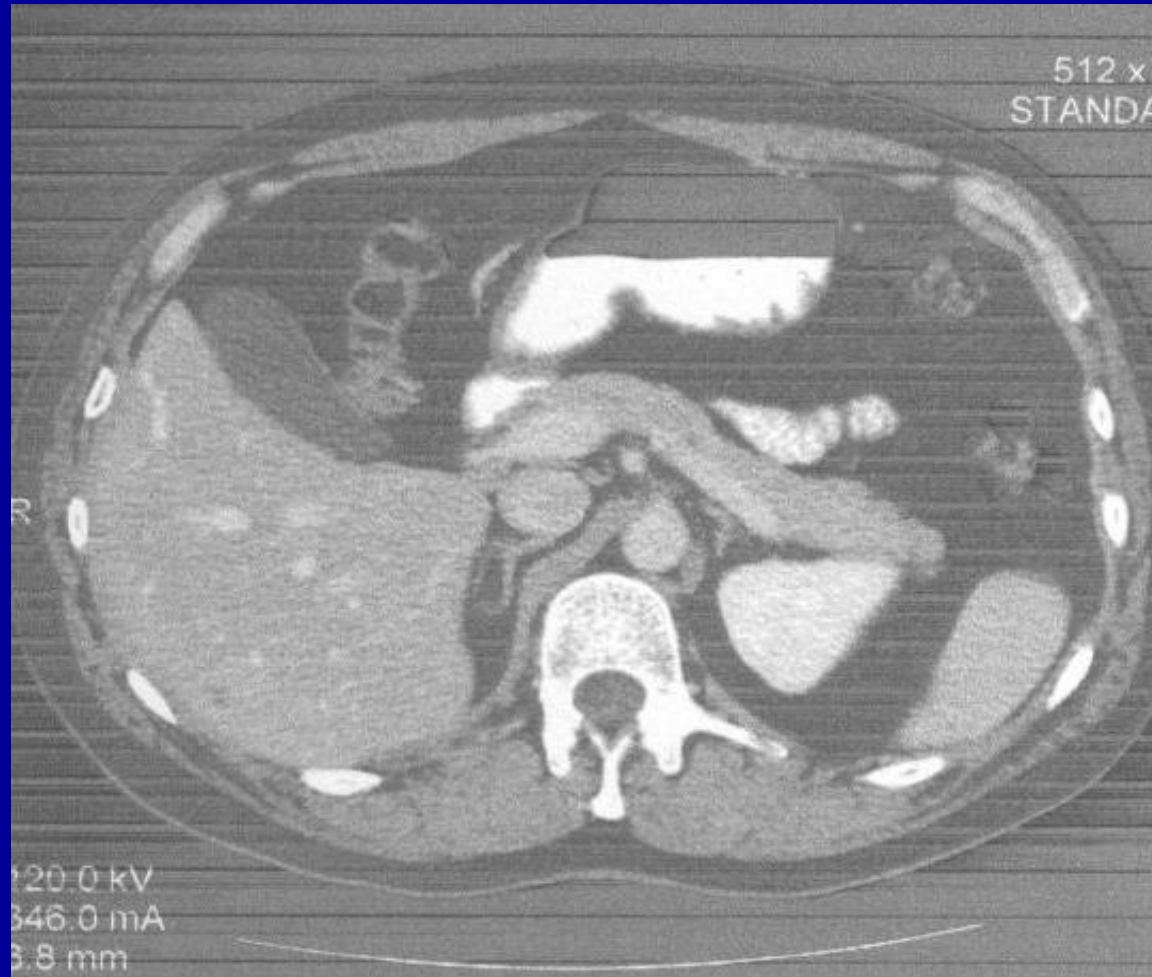


JA

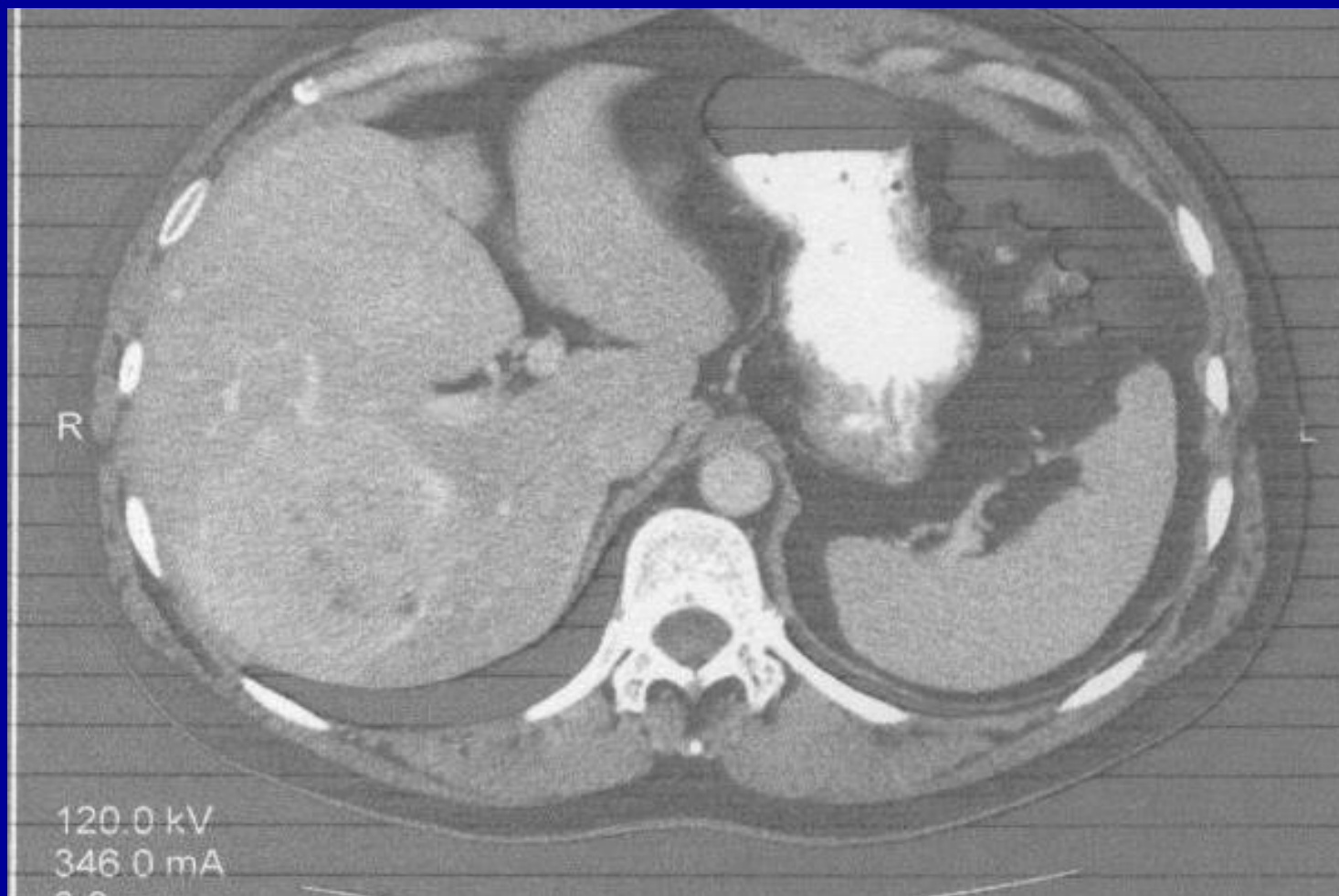CT scan 6 years following initial  
diagnosis

August 2008

AUGUST 2008



AUGUST 2008



MRS. JK  
PANCREATIC CANCER

80 year old female from San Francisco.

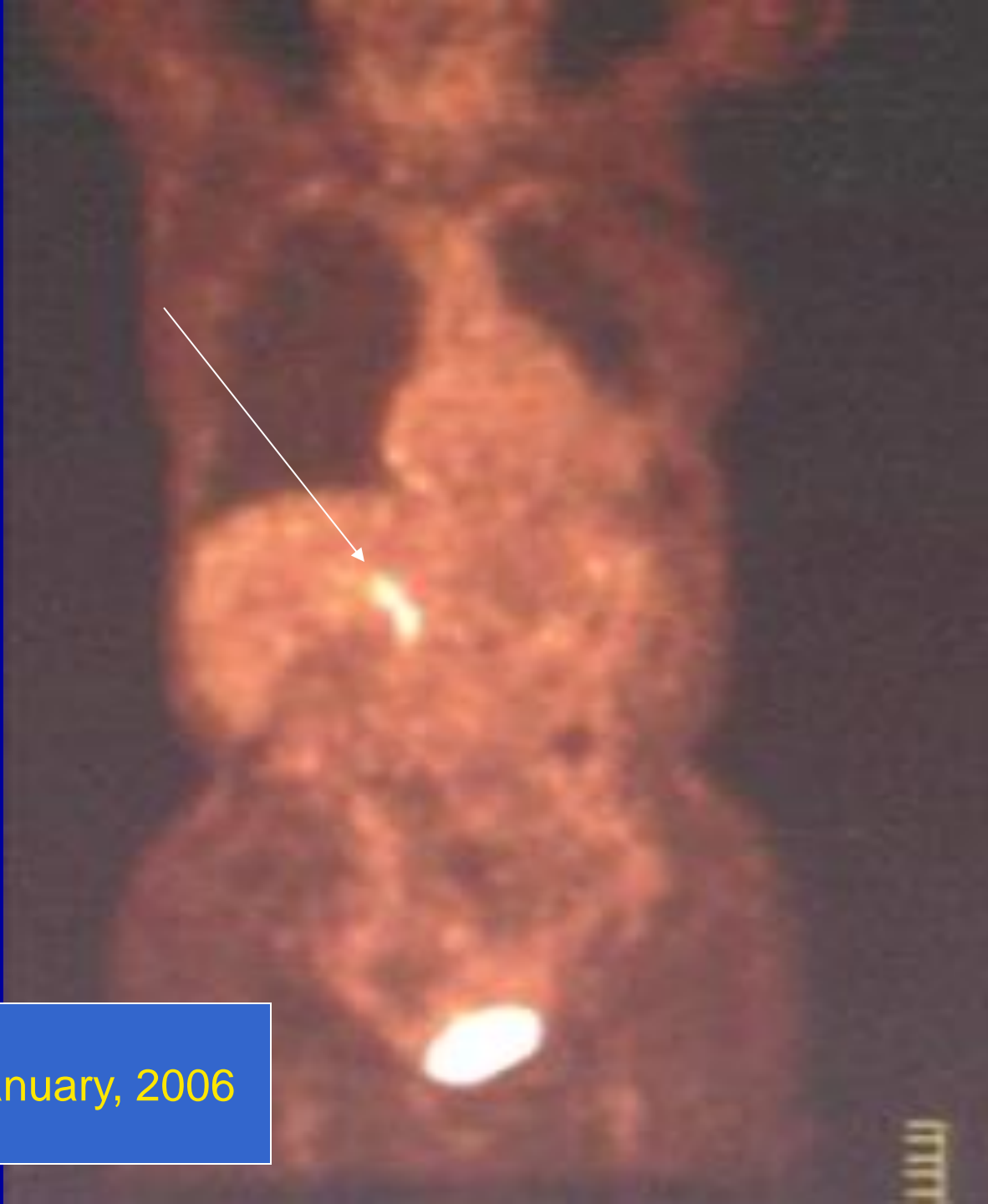Painless jaundice.

CT scan in November 2005 showed a pancreatic head tumor with possible liver involvement. Ca 19-9=356

Placement of internal biliary shunt.

JK refused chemotherapy.

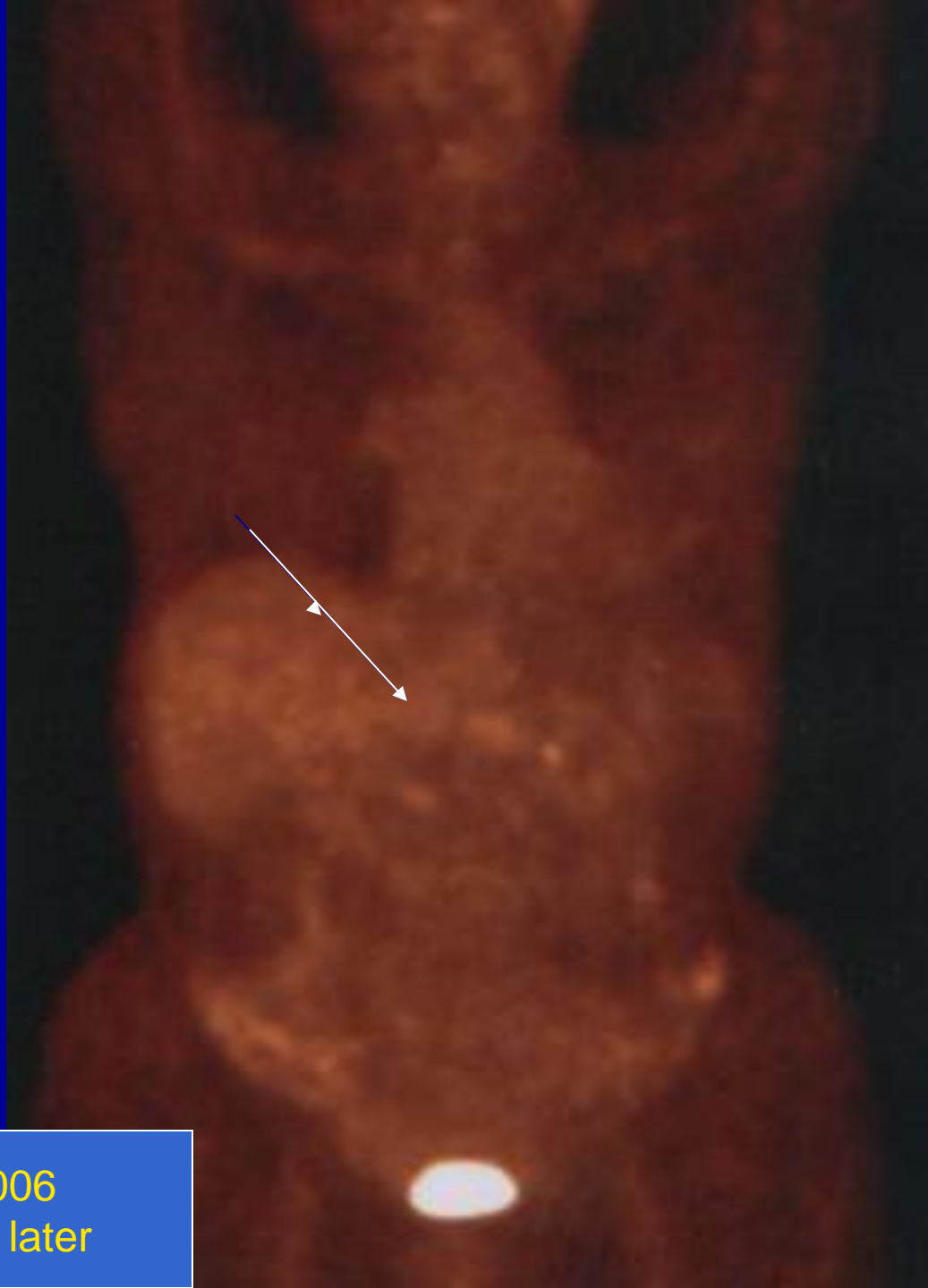



PET Scan, January, 2006

Mrs. JK

- Same protocol as JA



June 2006  
6 months later

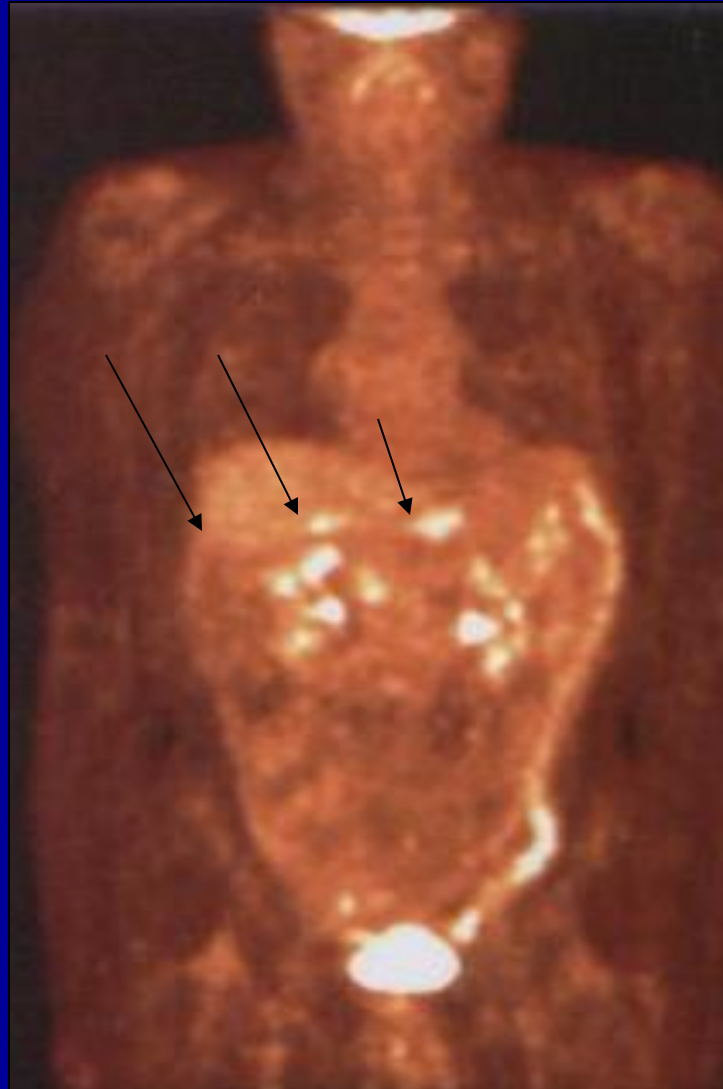
## MRS. JK

- Large tumor seen on PET scan November 2005
- No tumor seen on PET scan June 2006.
- Treatment with LDN 4.5mg. Qhs and ALA.
- Healthy life-style and diet supplemented with ALA orally and intravenously two times a week and various vitamins.

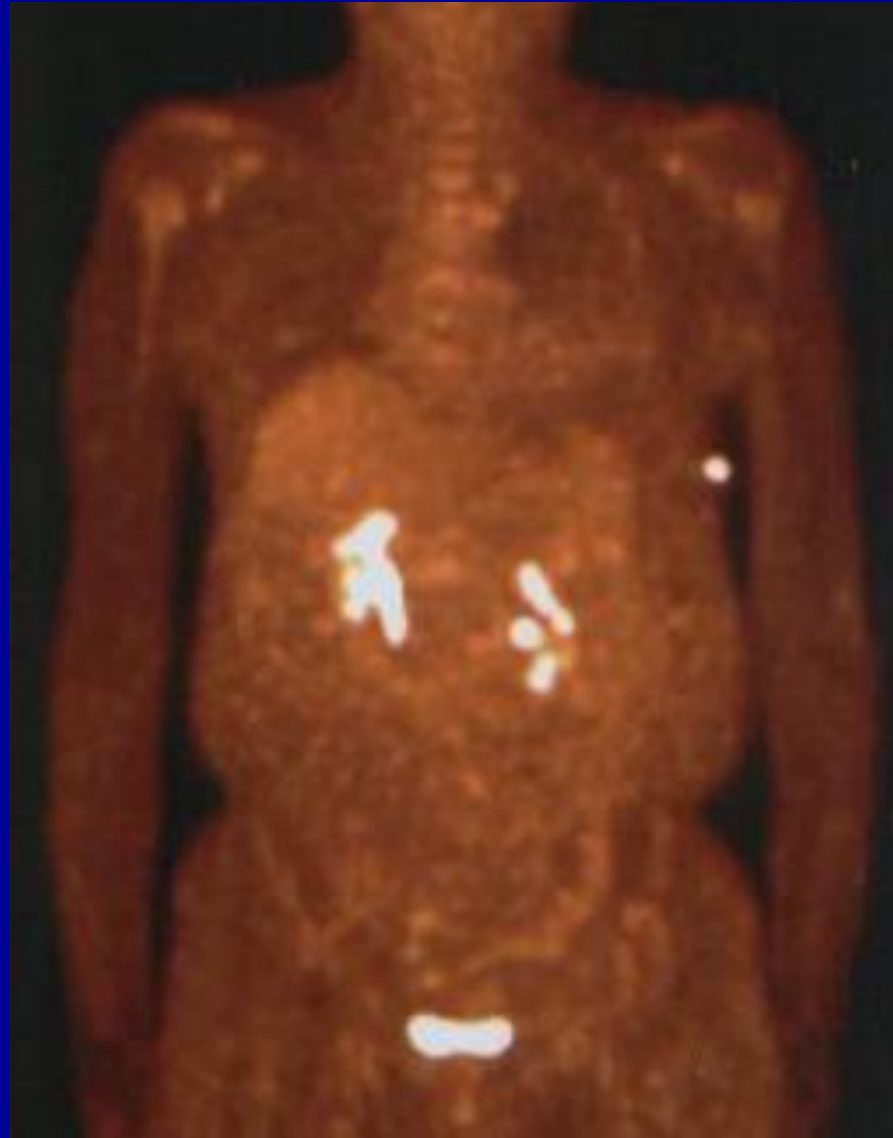## MR. RC PANCREATIC CANCER

- 67 year old male from Chicago arrived IMCNM November 2006.
- Post brachy-therapy for prostate cancer.
- Post chemotherapy for B-cell lymphoma
- Pancreatic cancer with metastases to liver May 2006.
- Treated with ALA/N starting November 2006..
- Not adherent to life-style or diet.

FIRST PET SCAN  
NOVEMBER 2006



FEBRUARY 2007



## Mr. RC

- Continued ALA/N until February, 2007.
- His CEA dropped from 53.6 to 2.6 and his CA 19-9 dropped from 146 to 113.
- RC felt so good that he scheduled surgery to have an internalization of his external biliary drain in San Diego.
- The California oncologist recommended a course of Gemcitabine just to be safe.  
Oncologist took RC off ALA/N
- RC developed septicemia and expired in the hospital.



# THE LONG-TERM SURVIVAL OF A PATIENT WITH PANCREATIC CANCER WITH METASTASES TO THE LIVER

Berkson BM, Rubin DM, and Berkson AJ  
Integrative Cancer Therapies  
Volume 5, Number 1, March 2006

REVISITING THE ALA/N PROTOCOL FOR  
PEOPLE WITH METASTATIC PANCREATIC  
CANCER  
REPORT OF 3 NEW CASES

Berkson BM, Rubin DM, Berkson AJ.  
Integr Cancer Ther. 2009 Dec;8(4):416-22.PMID: 20042414

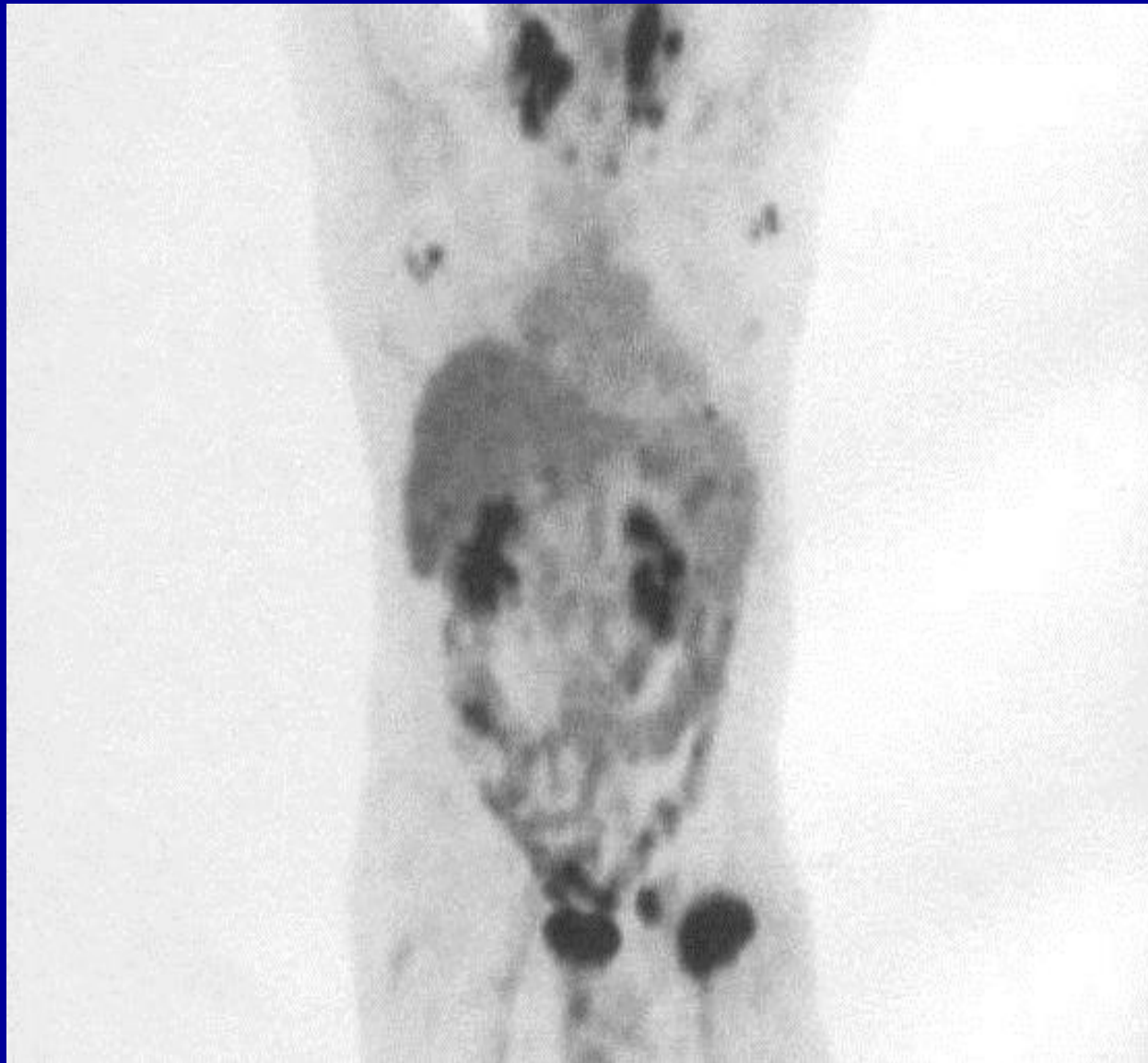
Mr. TM  
B-cell lymphoma  
December, 2005

- 62 YO male in construction business.
- Biopsy=B-cell non hodgkins lymphoma.
- Lymphoma started after EBV infection and Bells Palsy.

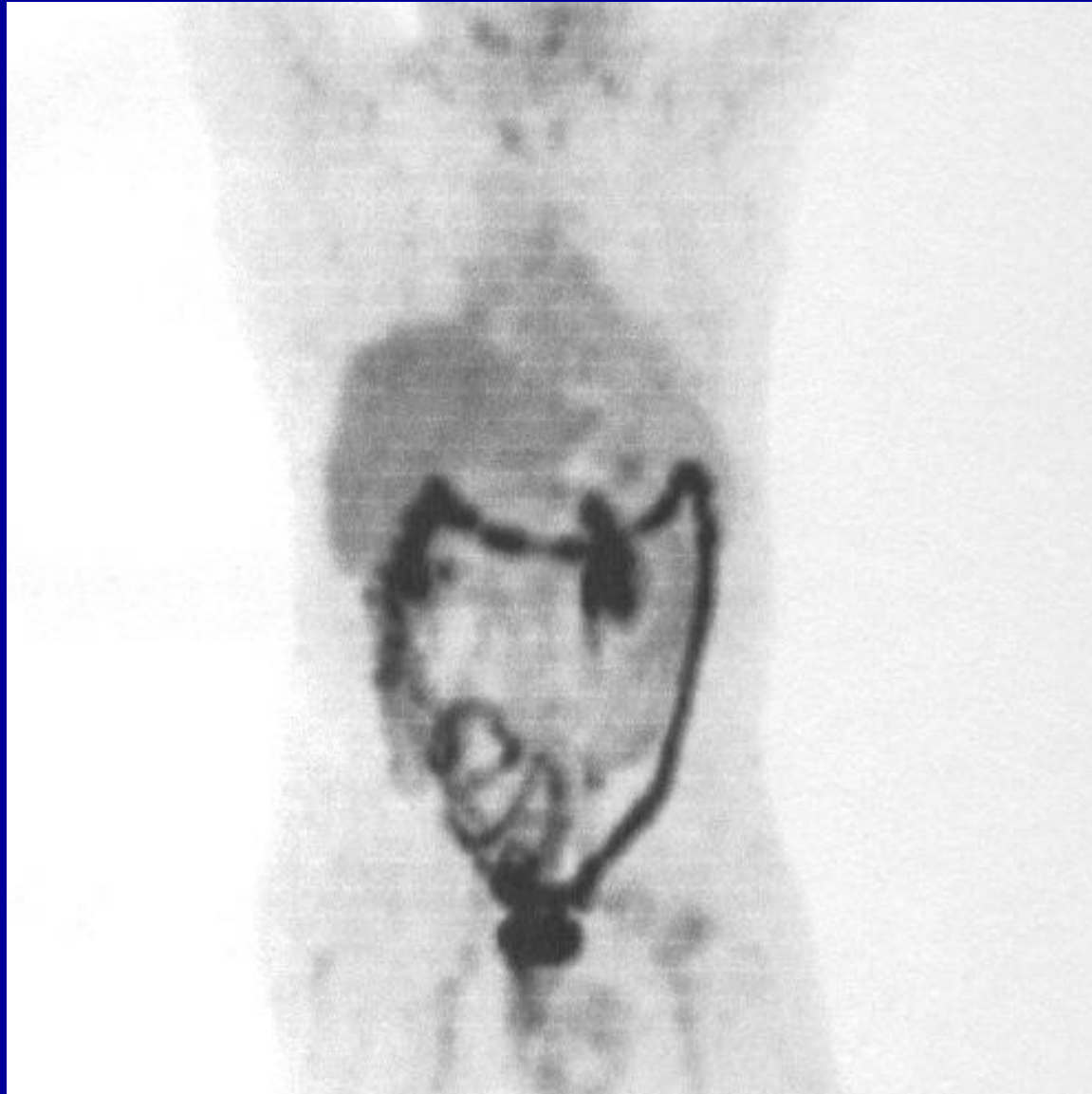# MR. TM TREATMENT PROGRAM

- 4.5 mg. LDN at bedtime.
- Had only 2 weeks of IV ALA.
- Not adherent to life style, diet, or supplement regimen.

MR TM



MR. TM  
MAY 2006



# REVERSAL OF SIGNS AND SYMPTOMS OF A B-CELL LYMPHOMA PATIENT USING LDN

BERKSON BM, RUBIN DM, BERKSON AJ

Integr Cancer Ther. 2007 Sep;6(3):293-6.





# SUMMARY

- A few interesting case histories.
- Several others are alive and doing well.
- Several have died.
- I don't think ALA/N cures cancer, however, with several people, it prolongs their lives and sometimes reverses the disease process and they live for years free of the disease.
- ALA/N is most effective for autoimmune disease.  
The ALA/N protocol works best with lupus and RA.

Burton M. Berkson MD MS PhD

## Books describing therapies

Also type in Berkson BM on Google, Google Scholar, or PubMed

