



Case Report/Relato de Caso

Recurrent herpes simplex infections: laser therapy as a potential tool for long-term successful treatment

Herpes *simplex* recorrente: laser terapia como método alternativo para tratamento a longo prazo

Dennis Carvalho Ferreira^{1,2}, Helena Lucia Barroso Reis^{2,3}, Fernanda Sampaio Cavalcante¹, Kátia Regina Netto dos Santos¹ and Mauro Romero Leal Passos²

ABSTRACT

Herpes simplex virus types 1 and 2 are the main infectious agents associated with oral and genital ulcerations. These infections are now widely recognized as sexually transmitted diseases. Among treatment options, low-level laser therapy (LLLT) has shown promising clinical results as a longer-lasting suppression therapy. Two clinical cases are described with recurrent labial herpes for which LLLT was used. Following treatment, both patients remained symptom free during the 17-month clinical follow-up period.

Keywords: Low-level laser therapy. Herpes simplex type 1. Herpes simplex type 2.

RESUMO

Os vírus do herpes *simplex* tipos 1 e 2 são os principais agentes infecciosos associados às ulcerações orais e vaginais. Estas infecções são amplamente reconhecidas como doenças sexualmente transmissíveis. Entre as opções de tratamento, o laser de baixa intensidade (LBI) mostrou resultados promissores como terapia de supressão de longa duração. Descrevemos dois casos clínicos com herpes labial recorrentes nos quais o LBI foi utilizado que permaneceram assintomáticos durante 17 meses de controle clínico.

Palavras-chaves: Laser de baixa intensidade. Herpes *simplex* tipo 1. Herpes *simplex* tipo 2.

INTRODUCTION

Oral and genital herpes infection are the most common manifestations of HSV (Herpes simplex viruses), and type 1 (HSV-1) and type 2 (HSV-2) are the main causative agents. HSV-2 infects the orolabial region, with few recurrences and causes herpes genitalis, one of the most common sexually transmitted diseases in the world. HSV-2 rarely appears prior to the onset of sexual activity. Both viral HSV-1 and HSV-2 can present clinical manifestations¹.

HSV infection is spread by direct contact with mucosal surfaces or skin traveling from nerve endings to ganglions. The virus can remain latent for indefinite periods of time and is noninfectious

during the latency period. However, horizontal transmission can occur due to viral replication².

HSV-1 and HSV-2-induced ulcers cause discomfort to patients, manifested as itching, tingling and pain with functional and esthetic implications where local trauma is present³.

Currently, an estimated 85% of the world population is seropositive for HSV-1 and primary infection generally occurs during childhood and adolescence¹. Herpes diagnosis is achieved by assessing the patient's history and physical examination. However, further tests are necessary when HSV infection is asymptomatic, subclinical or atypical, or shows wide expression. Different methods of HSV identification and treatment of oral cavity lesions are available, including the use of oral, intravenous or topical antiviral medications, such as acyclovir, valacyclovir, foscarnet, imiquimod. Low-level laser therapy (LLLT) can be used in association with conventional therapy. The choice of treatment method will depend on the number, location and size of the lesions, as well as on cost-effectiveness and the availability of resources⁴.

LLLT has been used to treat a number of conditions, particularly herpes simplex 1 and 2, permitting the host cells to remain viable, with *in vitro* results indicating a decrease of 68.4% and 57.3% in acyclovir-resistant HSV-1 and HSV-2, respectively⁵. LLLT presents both antiinflammatory and analgesic effects, contributing to tissue repair and fibroblast proliferation and an increase in the interval between infections; moreover, it does not contribute in viral resistance.

Two clinical cases in which LLLT reduced the clinical course and recurrences, alleviating pain and discomfort after a 17-month follow-up, are reported.

CASE REPORT

A 23 year old, white, heterosexual male patient, a nursing graduate student living in Rio de Janeiro, was suffering from work-related stress. He reported five episodes of lesion manifestation below the lower lip during a one year period. He was referred to the Sexually Transmitted Diseases (STD) Unit of the Fluminense Federal University (*Universidade Federal Fluminense, UFF*) for treatment, where he presented hyperemic lesions with vesicles and itching in the region. He had been previously diagnosed with impetigo, for which topical antibiotics were prescribed, with no improvement.

He reported multiple sexual partners and irregular condom use for vaginal, anal and oral sex. A pack-a-day smoker and daily alcohol

1. Instituto de Microbiologia Paulo de Góes, Universidade Federal do Rio de Janeiro, Rio de Janeiro, RJ. 2. Setor de Doenças Sexualmente Transmissíveis, Departamento de Microbiologia, Universidade Federal Fluminense, Rio de Janeiro, RJ. 3. Hospital Universitário Cassiano Antônio de Moraes, Universidade Federal do Espírito Santo, Vitória, ES.

Address to: Dr^a Helena Lucia Barroso Reis. HUCAM/UFES. Av. Marechal Campos 1468, 29055-180 Vitória, ES, Brasil.

Phone: 55 27 3335-7180

e-mail: hbarroso@unimedvitoria.com.br

Received in 19/10/2010

Accepted in 01/02/2011

consumer, the patient had not seen a doctor on a regular basis. He reported being diagnosed with gonorrhea two years before, which was properly treated.

He presented a lesion below the lower lip of 3.5cm in diameter, a hyperemic area with ulceration, vesicles, itching and secretion material that could be expelled (**Figure 1**, letter A). This was associated with cervical unilateral lymphadenopathy.

Cytopathological examination revealed nonspecific inflammatory alteration (**Figure 1**, letter B). He tested negative for anti-HIV, VDRL and viral hepatitis and positive for anti-HSV IgM. The genital area presented no alterations.

Four sessions of low intensity laser (red light) were performed with a DMC Photon Laser II. The dose of LLLT for each session was 30J/cm², with 660nm continuous emission wavelength at a power density of 100mW, applied to the lesion region for 8s. Five laser applications were performed for the herpes lesion. Four points surrounding the lesion were selected to receive 5 applications each, totaling 20 applications. Remission was observed after 7 days (**Figure 1**, letter C) and no recurrences were observed during the 17 month follow-up period.

Case 2

The patient was a 50 year old, white, heterosexual female physiotherapist, living in Rio de Janeiro with recurrent episodes of labial herpes in the preceding 5 years. She was referred to the STD service provided by the UFF, RJ.

She reported nonexclusive sexual relations, with systematic condom use for vaginal and oral sex. She was a non-smoker, a social drinker, and non-user of illegal substances.

She complained of hyperemia and pain in the labial and perioral areas after sun exposure and reported family stress. Lesions, initially of vesicular type, eventually evolved into more serious ulcerations, causing discomfort. The patient reported that the episode had begun five days before, and was preceded by 2-3 monthly relapse episodes.

Examination showed an extensive vesicular lesion with ulcerations around the mouth and lips (**Figure 2**, letter A), which was associated with cervical unilateral lymphadenopathy.

Cytopathological examination revealed multinucleation with molding, suggesting herpes virus infection (**Figure 2**, letter B). She tested negative for HIV, VDRL, and viral hepatitis, but positive for anti-HSV IgM. No alterations were observed in the genital area.

Five sessions of low intensity laser (red light) were performed with a DMC Photon Laser II. The dose of LLLT in each session was 30J/cm² with 660 nm continuous emission wavelength at a power density of 100mW, applied to the lesioned region for 8s. Twelve points were selected on the lesions for laser application. For each point, five applications were performed, totaling 60 applications. Remission was observed after 5 days (**Figure 2**, letter C) and no recurrences were observed during the 17 month follow-up period.

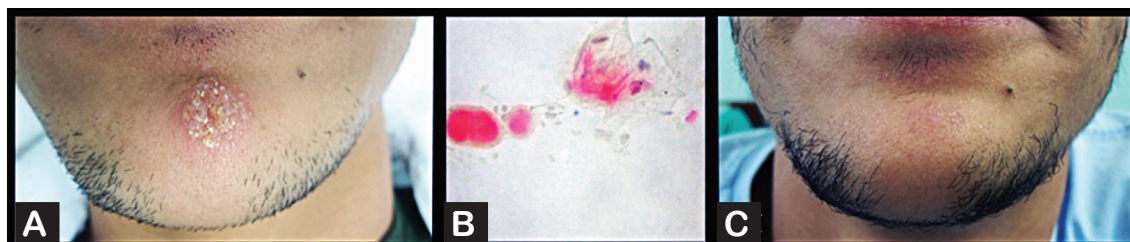


FIGURE 1 - A: Patient 1 presenting an ulcerative lesion in perioral region. B: Cytopathology of the lesion of the patient 1 - demonstrating binucleation and nuclear molding . C: Patient 1 after laser sessions with no injuries.

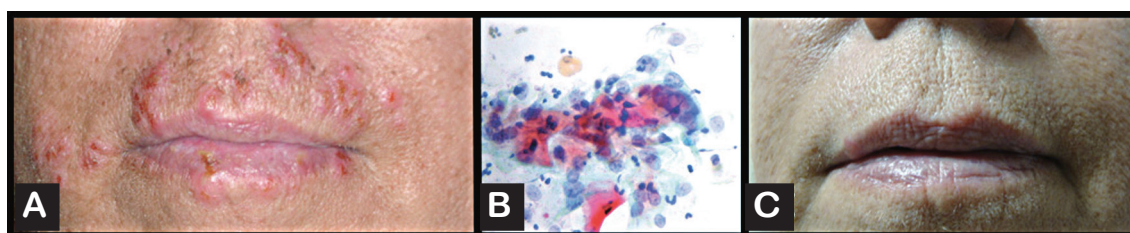


FIGURE 2 - A: Patient 2 showing ulcerative lesions along perioral and lip extension. B: Cytopathology of the lesion of the patient 2 - demonstrating karyomegaly, multinucleation and nuclear molding (HE). C: Patient 2 after laser sessions without clinical manifestation.

DISCUSSION

Low-level laser therapy (LLT) as an alternative treatment method for oral mucositis and ulcerative lesions in the oral cavity has been documented in the literature⁶. However, its efficacy in long-term suppression of herpes simplex infections has yet to be established. *In vitro* and *in vivo* studies have been conducted^{7,8} and positive outcomes have been shown to be directly related to the number of treatment sessions and the virus type.

A combined course of treatment with topical and systemic acyclovir therapy was initially suggested, but our patients refused this due to previous frustrating experiences with the drug. Due to the positive *in vitro* results and the promising outcomes reported in the literature, LLLT was offered to patients as a treatment option.

The clinical presentation of the patients shared close similarities with the examples described in the literature, which could help envisage a future protocol for clinicians: three recurrences of clinical HSV lesions in a 12-month period; recurring herpes labialis for at least three subsequent years; pain or discomfort symptoms associated

with esthetic problems; HIV-free; and use of systemic and topic acyclovir for at least two episodes of recurrent infection^{7,8}.

LLLT treatment sessions were performed in accordance with the *in vitro* study previously reported by Ferreira et al and with the regimen described by the manufacturer. The two cases studied indicate the need for longitudinal studies, in order to establish LLLT treatment protocols for infectious agents and other related microorganisms and for a range of immunosuppressed patients, for whom a generally accepted treatment course has yet to be described⁷.

The analysis performed was focused on aspects that could be generalized for the treatment course of a wide range of ulcerative lesions of the oral cavity: location; underlying conditions or associated infections or coinfections; impact on the quality of life; functional discomfort; skin trauma; and that feasibility of a clinical evaluation of the patient's partner^{7,8}.

Currently, no definitive therapy has been described for HSV infections; however, medications and laser therapy (LLLT) could reduce the severity and recurrence of lesions. Researchers have emphasized that higher success rates are obtained with early diagnosis. Acyclovir remains the drug of choice for HVS, but it is expensive and may induce viral resistance, particularly in immune deficient patients or in those being treated with immunosuppressors.

In this study, repeated relapses led the patients to refuse further acyclovir therapy and search for an alternative treatment. A preestablished protocol for LLLT was used to select the number, location, and extension of the points covered in each session for the patient. For patient 2, who had more extensive and painful ulcerations, LLLT was suggested, since its biostimulating properties promptly reduce discomfort and pain, while simultaneously accelerating tissue reparation. Moreover, LLLT preserves the tissues and can be repeatedly used without posing a serious risks to the patient, as shown by *in vitro* studies, where cells were maintained 100% viable when the same protocol was used^{7,8}.

The management of herpetic infection is indeed challenging, since none of the different methods of treatment guarantees full remission⁹. This preliminary study aimed to describe the absence of relapses and their clinical manifestations after a one-year period, with a variation of 3-4 months. However, further studies are required to clarify on which stage of the HSV replication cycle LLLT acts and when productive infections with ulcerative lesions set in. HSV-1 control strategies, such as anti-herpetic vaccines, are still at an experimental but promising stage, which may eventually lead to a solid immunoprophylaxis⁹.

REFERENCES

1. Wutzler P, Doerr HW, Färber I, Eichhorn U, Helbig B, Sauerbrei A, et al. Seroprevalence of herpes simplex virus type 1 and type 2 in selected German populations-relevance for the incidence of genital herpes. *J Med Virol* 2000; 61:201-207.
2. Malkin JE. Natural history of HSV1 and HSV2 transmission modes and epidemiology consequences of HSV infection on HIV infection. *Prevention. Ann Dermatol Venereol* 2002; 129:571-576.
3. Drake S, Taylor S, Brown D, Pillay D. Improving the care of patients with genital herpes. *BMJ* 2000; 321:619-623.
4. Siegel MA. Diagnosis and management of recurrent herpes simplex infections. *J Am Dental Assoc* 2002; 133:1245-1249.
5. Fatahzadeh M, Schwartz RA. Human herpes simplex labialis. *Clin Exp Dermatol* 2007; 32:625-630.
6. Schindl A, Neumann R. Low-intensity laser therapy is an effective treatment for recurrent herpes simplex infection. Results from a randomized double-blind placebo-controlled study. *J Invest Dermatol* 1999; 113:221-223.
7. Ferreira DC, Martins FO, Romanos MTV. Impacto do laser de baixa intensidade na supressão de infecções pelos vírus Herpes simplex 1 e 2: estudo *in vitro*. *Rev Soc Bras Med Trop* 2009; 42:82-85.
8. Carvalho RR, Paula Eduardo F, Ramalho KM, Antunes JL, Bezinelli LM, Magalhães MH, et al. Effect of laser phototherapy on recurring herpes labialis prevention: an *in vivo* study. *Lasers Med Sci* 2010; 25:397-402.
9. Koelle DM. Vaccines for herpes simplex virus infections. *Curr Opin Investig Drugs* 2006; 7:136-141.